

Orofacial Myofunctional Therapy – The Critical Missing Element to Complete Patient Care

by Joy Moeller, BS, RDH, COM

Educational objectives

Upon completion of this course, participants should be able to achieve the following:

- Define orofacial myofunctional therapy.
- Recognize oral and facial muscle pattern abnormalities.
- Understand proactive intervention modalities that a dentist or orthodontist in private practice can utilize.
- Educate the professional as to the value of early treatment and prevention.
- Learn how noxious habits might affect growth and development.

I have been a dental hygienist and a myofunctional therapist for more than 30 years. I learned about myofunctional therapy in 1978 from the dentist I worked with. My son, who had TMD, a low tongue rest posture, no lip seal, crowding, mouth breathing, (I am sure he had apnea symptoms), and chronic headache pain was helped tremendously by a combination of myofunctional therapy, cranial osteopathic therapy and a bite splint. Not only did his headaches and TMD issues improve, but his palate widened and allowed his teeth to erupt in a more normal position. I continue to spread the word that this treatment works to stabilize the muscles and address the cause of many problems instead of chasing the symptoms.

This is a “green” treatment, which your patients will love. They *want* this treatment because they actually have an active role in correcting the problem, which is proactive in preventing major issues and in treating orofacial myofunctional problems when they do occur.

The purpose of this article is to give you an overview of oral myology, which is the critical missing element to complete patient care. You can find a qualified therapist in your area by visiting the directory page on www.iaom.com. The interdisciplinary approach to patient wellness is important because the teeth, the bones and the muscles must work in harmony to attain occlusal stability.

The goals of oral myology are.

1. Promoting a lip seal.
2. Promoting a palatal tongue rest position.
3. Promoting a posterior, tooth together swallow.ⁱ
4. Facilitating bi-lateral chewing and correct drinking.ⁱⁱ
5. Keeping hands and objectives away from the face.
6. Facilitating nasal breathing.
7. Developing a harmonious peri-oral muscle pattern.
8. Correcting dysfunctional habit patterns.

Myofunctional therapy, also called orofacial myology, is the neuromuscular re-education or re-patterning of the oral and facial muscles. It might include muscle exercises, which create a normal freeway space dimension.ⁱⁱⁱ Therapists are trained to eliminate negative oral habits through



Dentaltown is pleased to offer you continuing education. You can read the following CE article in the magazine, take the post-test and claim your two ADA CERP or AGD PACE continuing education credits. See instructions on page 76.

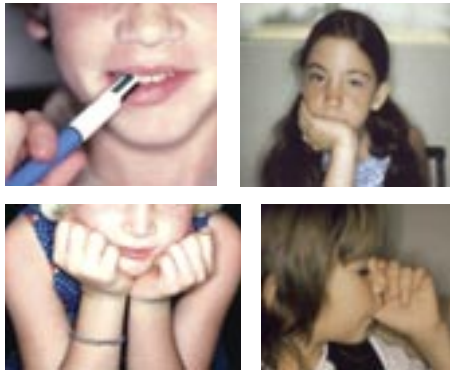ADA CERP® | Continuing Education Recognition Program

Farran Media is an ADA CERP Recognized provider. ADA CERP is a service of the American Dental Association to assist dental professionals in identifying quality providers of continuing dental education. ADA CERP does not approve or endorse individual courses or instructors, nor does it imply acceptance of credit hours by boards of dentistry.



Approved PACE Program Provider
FAGD/MAGD Credit
Approval does not imply acceptance by a state or provincial board of dentistry or AGD endorsement.
12/01/2004 to 12/31/2012

For more information, go to <http://www.towniecentral.com/Dentaltown/OnlineCE.aspx>



behavior modification techniques and promote positive growth patterns. We train people to breathe through their noses if their airways are not compromised, and if the oral breathing is an acquired habit; we teach people how to properly position their tongue at rest; we teach how to chew and swallow correctly, and we emphasize the importance of proper head and neck posture patterns.

The history of myofunctional therapy dates back to the 1400s in Italy. In the United States, in 1906 Alfred Rodgers, an orthodontist experimented with facial muscles exercises and in 1918, wrote a paper titled, "Living Orthodontic Appliances," in which he cited that muscle function alone would correct malocclusion with no need for retention. In 1907, Edward H. Angle, an orthodontist wrote an article on the effects of habits on occlusion. In 1925, Harvey Stallard, a dentist in San Diego, researched 7,000 children on sleep position and malposed tooth buds. He maintained that sleeping on the face, during a child's formative years, could create malocclusion.

In the 1930s, Weston Price, a dentist, researched primitive or traditional cultures.^{iv} He looked at people all over the world, examined what they ate and evaluated their oral health. He found that primitive cultures, when compared to "modern" cultures, had very little dental disease and their jaw relations and occlusion were healthy. In the 1960s, Walter Straub, an orthodontist, published research on bottle feeding and how it affects occlusion.^v

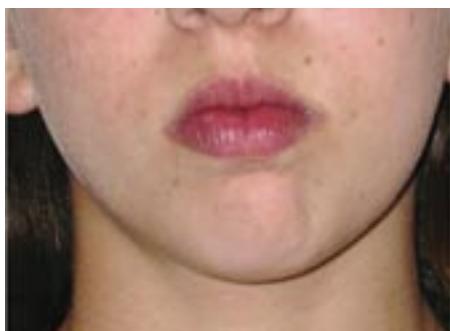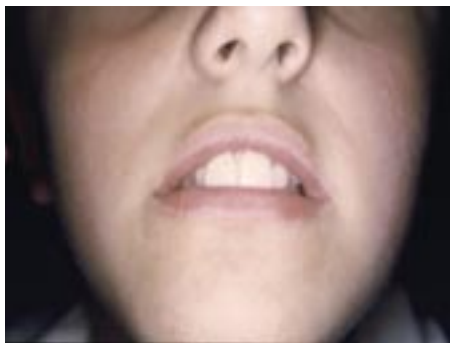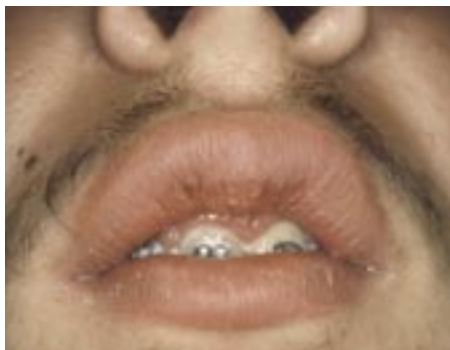
Many times oral habits, beginning in infancy, are carried forward into childhood and then adulthood. Some well known ones are thumb, tongue or finger sucking, cheek, lip or tongue chewing, nail biting, clenching or grinding, hair chewing, leaning on the face, pen or pencil chewing and many others. I call this the "remembered endorphin rush," which starts in infancy with sucking. As a myofunctional therapist, I promote replacement of the habits with having the tongue resting up on the palate. In my experience this seems to stimulate enough endorphins to help stop the noxious habit.

Some of my patients are habitual gum chewers. Gum chewing is not damaging if done in moderation. I have three rules when it comes to gum:

1. Chew only after eating.
2. Alternate chewing on both sides to prevent a TMD or bite problem.
3. Limit chewing to five or 10 minutes only. (Of course, with xylitol gum only!)

Mouth breathing might cause the tongue to rest down and is often associated with "long faced syndrome," orthodontic relapse, allergies, periodontal disease, and sleep disorders.^{vi} What causes mouth breathing? Otolaryngologists and ENTs cite several causes, including what I call "sensitivities to the three Ds: dust, dairy products and animal dander, which might contribute to congestion and nasal airway obstruction and might encourage mouth breathing. Mouth breathing, sucking habits and tongue thrusting are all etiological factors to orofacial myofunctional disorders. Also, tight lingual frenum attachments can cause a low tongue rest position. A tight labial frenum could be associated with a short upper lip. This leads to a lack of lip seal, which is important for good occlusion.^{vii} These, in addition to grimacing when swallowing are some things to look for in the evaluation of oral facial myofunctional disorders.

Diagnosis of an oral muscle pattern problem might include chewing with the mouth open, smacking and other irritating noises while chewing, an overdeveloped mentalis muscle and a facial grimace during swallowing, and especially a low tongue rest position. If the tongue habitually rests down, the palate might not develop properly, and a high vault palate is a common occurrence in orofacial myofunctional disorders.^{viii}



Mouth breathing and a low tongue rest posture are often associated with a forward head posture. The person brings their head forward in order to open the airway. Carrying heavy back packs or poor posture while working at the computer seem to exacerbate the overall postural problem.^{ix}

Myofunctional therapy might enhance a person's quality of life. The occlusion, the airway, and posture may change due to the muscle adaptation.

Some other etiologies of a myofunctional problem might be artificial or incorrect infant feeding,^x short or restricted labial or lingual frenum,^{xi} not being held enough as an infant,^{xii} genetic predisposition, large palatal tonsils,^{xiii} oral trauma,^{xiv} brain injury,^{xv} allergies,^{xvi} or macroglossia.^{xvii} Also, pacifiers and bottle-feeding might create a sucking habit and push the mandible down and back interfering with proper development.^{xviii}

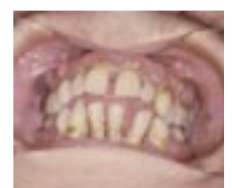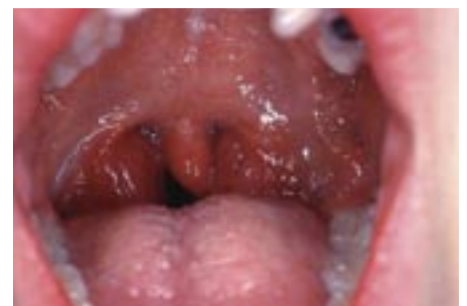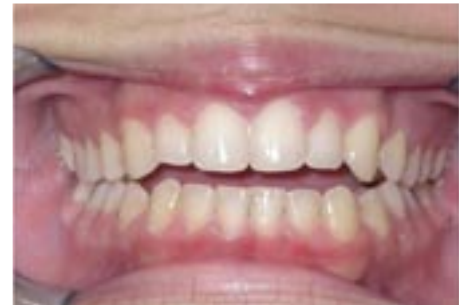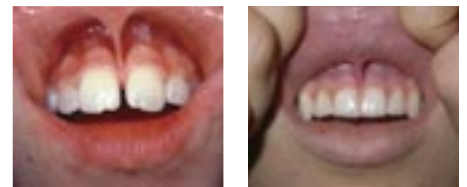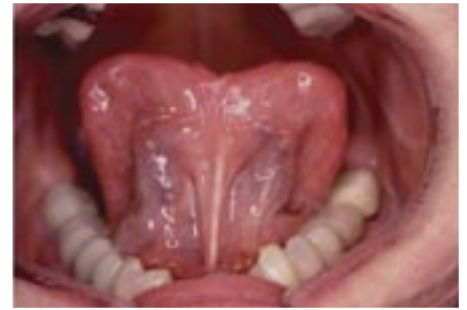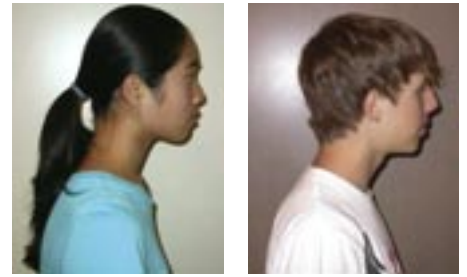Frenum attachments, both labial and lingual, that restrict proper function, should be released by an oral surgeon, a periodontist, an ENT, or a trained dentist as soon as possible. Historically, as soon as a baby was born, the baby's frenum was released. Breast feeding was a matter of survival and if the baby had a difficult time latching on the breast, the baby could die. Now we have an option to bottle feed our babies. What we do not realize is that the baby who is bottle-fed exclusively, might later develop an orthodontic problem.^{xix} If the children are tongue tied, their tongue rests low on the floor of the mouth most likely contributing to a development of tongue thrust or high narrow palate. Also, they cannot swallow properly. At least two percent of all infants born need to have their frenums clipped.^{xx} It is much easier to have the tongue and lips frena done early and prevent as much as possible speech, dental, and orofacial functional problems. Now that lasers are commonly used in dentistry, some dentists use a soft tissue laser to sever the connective tissue frenum, unless it is a lingual posterior tongue-tie, which would require an oral surgeon to surgically assist by releasing the muscle fibers. Some oral surgeons feel that lasers might leave scar tissue to cause more problems. I have found if the patient will do myofunctional exercises after the surgery, scar tissue is minimal and function is adequate or optimal.

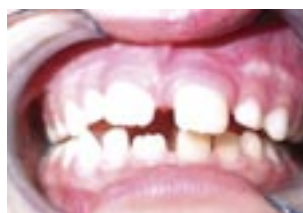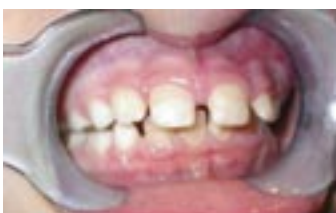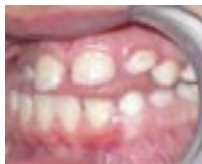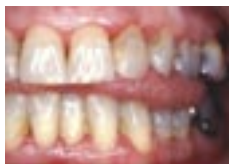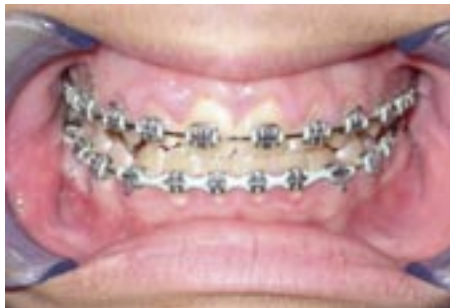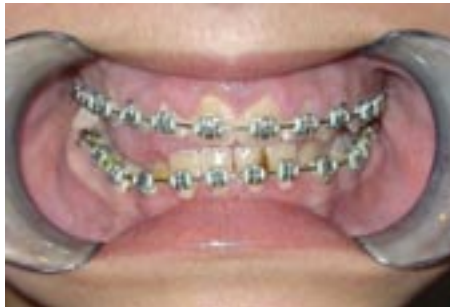We work hand in hand with ENTs and Allergists in promoting correct nasal breathing and lip seal. Working together with the patient, we can achieve a palatal tongue rest posture, which will assist the orthodontist or functional dentist in achieving long term occlusal stability.

Large or infected tonsils might cause problems with swallowing. If the tonsils are large or infected constantly, the back of the tongue has to come forward to swallow because there is no room or it is painful to swallow correctly. Also, the airway might be blocked and the mouth breathing causes the tongue to rest down and forward.

Periodontal disease is now linked to heart disease and diabetes.^{xxi} If a patient mouth breathes, anterior gingivitis is prevalent.^{xxii} When will periodontal therapy include orofacial myofunctional treatment? Also, when the tongue is resting down and forward, the pressure of the tongue against the teeth may weaken the periodontal ligaments leading to traumatic occlusion and recession.

As dental hygienists, we all took vows to prevent dental disease. The proactive "green" treatment of myofunctional therapy might enhance the quality of life for many patients. Anterior or lateral tongue thrust patterns or resting positions are associated with open bites and swallowing pressure is directed forward and down rather than up and back.^{xxviii} This





might lead to a patient swallowing air, contributing to stomach aches, bloating, hiccups, burping and acid reflux, also called GERD.^{xxiii}

Habits might affect the TMJ.^{xxiv} Harmonious muscle pattern is important to correct a muscle related TMD. Myofunctional therapists are trained to eliminate habits, which might affect the TMJ. Also, habitual grinding and clenching affect the masseters and temporalis muscle function. It is always best to do the least invasive treatment first.

Orthognathic surgery relapses and orthodontic relapses might, many times, be prevented by myofunctional therapy.^{xxv} We can adapt the muscle patterns to the new bite and bone structure. In this way, we can be an important team player in the maintenance of a stable result.

Many dentists and orthodontists are now using functional appliances like the ALF appliance, the Bioblock, or the D&A appliance and myofunctional therapy to get fabulous results. Many times myofunctional therapy is built into the treatment plan from the beginning.

Myofunctional therapy might help the dental practice because patients want this treatment. In difficult financial times, people will understand the benefits of therapy. It is proactive and patients will really appreciate the referral. Thumb sucking therapy alone might make a huge lifestyle enhancement. We make it fun and easy to quit and the child feels proud and in control of his/her body. No more fighting the tongue and we might help to avoid orthodontic relapse from a low tongue rest position.

Four options I offer are:

1. Habit elimination therapy such as thumb sucking therapy.
2. Mini-Myo Program for the young child.
3. The standard myofunctional program.
4. A program for patients with special needs.

I currently teach four-day continuing education courses available to dentists, hygienists, and speech pathologists. It could be another profit center for the practice as well as helping patients proactively solve their orofacial myofunctional problems.

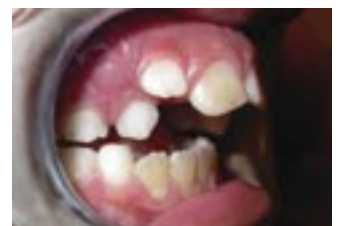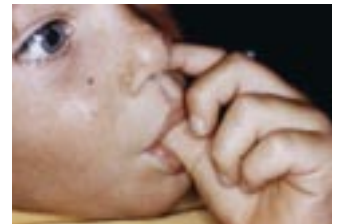Osteopathic physicians who specialize in manual medicine understand the value of myofunctional therapy. They deal with birth trauma, airway issues, headaches, and many, many problems. They help by releasing the restrictions in the proper movement of the body and might be a great asset to a multidisciplinary team that includes orofacial myologists.

Because sleep dentistry is rapidly becoming a major part of dental treatment today, myofunctional therapy might be a valuable asset to aid in obtaining a better result.^{xxvi}

By adapting the muscle patterns to the sleep appliance, and re-patterning the lip seal and the tongue rest posture, oral myologists might make wearing a sleep appliance more comfortable, which will contribute to a higher compliance of consistent use.

Treatment planning includes

1. Parafunctional habit elimination.
2. Intensive phase of a series of exercises to teach tongue rest position and establish a lip seal.
3. Introduce proper chewing and swallowing and correct functional head and neck posture.



4. The habituation phase which reinforces correct muscle memory pattern.

Therapy usually starts with establishing nasal airway (after clearance from an ENT and an Allergist) and developing a lip seal. If a patient habitually breathes through his/her mouth, the tongue rests down and the mandible drops down and back. The palate, in turn, might not develop correctly. A good myofunctional therapist will assist the patient to clear his/her nose, use correct abdominal (diaphragmatic) breathing, and then establish habitual nasal breathing.

Aesthetic changes from oral myology can motivate the patient to take a more active role in restoring teeth to create beautiful smiles.

The interdisciplinary or team approach is always the best. We must know what each other does and how together we can influence the prognosis for the best result possible and the best care possible.



If you would like to start a myofunctional aspect of treatment in your practice, send your hygienist or you, yourself, can attend a four-day class taught in areas all over the country. Go to www.myofunctional-therapy.com or www.aomtinfo.org for more information. ■

References

- i Manasha, An Explanation of the Effect That Two Different Swallowing Patterns Have on Cranial Articular Motion, *Journal of the Academy of Gnathologic Orthopedics*, June 2007
- ii Guimaraes and all, Effects of Oropharyngeal Exercises on Patients with Moderate Obstructive Sleep Apnea Syndrome, *American Journal of Respiratory and Critical Care Medicine*, 2009
- iii Mason, R. A Retrospective and Prospective View of Orofacial Myology, *International Journal of Orofacial Myology*, November 2005
- iv Price, W.A., *Nutrition and Physical Degeneration*, 1939, Price Pottenger Nutrition Foundation
- v Straub, Walter, Malformation of the Tongue, *American Journal of Orthodontics*, 1960
- vi Overland et all, Oral Breathing in patients with Sleep-Related breathing Disorders, *Acta Otolaryngol*, Sept. 2002
- vii Daenecke, S, et all, Anthropomedical Measurements of the height of the upper lip and length of the Philtrum, *Pro Fono*, Sept, 2006
- viii BourdiolPet all, Is the Tongue Position Influenced by the Palatal Vault Dimensions?, *J Oral Rehab*, Nov, 2009
- ix ChansirinukorW et all, Effects of Backpacks on Students: Measurements of Cervical and Shoulder Posture, *Aust J Physiother*, 2001
- x OvsenikM, Followup Study of Functional and Morphological Malocclusion Traits Changes from 3-12 Years Old, *European Journal of Orthodontics*, 2007
- xi DefabianisP, Ankyloglossia and its Influence on Maxillary and Mandibular Development, *Funct Orthod*, Oct 2000
- xii Singh, David, TMD Conference, San Diego 2005
- xiii Valera FC, et all, Muscular, Functional and Orthodontic Changes in Pre-School Children with Enlarged Adenoids and Tonsils, *Int J Pediatr Otorhinolaryngol*, July 2003
- xiv Kushner, CM and all, Fractures of the Growing Mandible, *Atlas Oral Maxillofac Surg Clin North Am*, Mar 2009
- xv LiuY, et all, 3D Ultrasound in Assessment of Growth and Development of Frontal Lobes in Children and Perinatal Brain Injury, *conf Proc IEEe Eng Med Biol Soc*, 2009
- xvi Baum, WF, et all, Delay of Growth and Development in Children with Bronchial Asthma, Atopic Dermatitis and Allergic Rhinitis, *Exp clin Endocrinol Diabetes*, 2006
- xvii ArkuszewskiPet all, A Method for Determination of Tongue Size in Patients with Mandibular Prognathism, *Ann Acad Med Stetin*, 2006
- xviii ZardettoCG, et all, Effects of different pacifiers on the primary dentition and oral myofunctional structures of preschool children, *Pediatr Dent*, 2002
- xix StraubWJ, Malfunction of the tongue: The Abnormal Swallowing Habit, Its Cause, Affects, and Results in relationship to Orthodontic treatment and Speech Therapy, *American Journal of Orthodontics*, 1962
- xx Marmet, C, Neonatal Frenotomy May be Necessary to Correct Breastfeeding Problems, *J Human Lact*, 1990
- xxi CullinanMP, Periodontal Disease and Systemic Health: Current Status, *Aust Dent J*, 2009
- xxii GulatiMS, et all, A Comparative Study of Effects of Mouth Breathing on Gingival Health in Children, *J Indian Soc Pedod PrevDent*, Sept 1998
- xxiii HenninkG, et all, Aerophagia: excessive air swallowing demonstrated by esophageal impedance monitoring, *Clin Gastro Enterol, Hepatol*, 2009
- xxiv OvsenikM, Incorrect Orofacial function until age 5 yrs of age and their association with posterior crossbite, *AmJ ort hod Dentofacial orthop*, Sept, 2009
- xxv BrusatiR, et all, Functional Results after Condylectomy in active laterognathia, *J Craniomaxillo fac surg*, June, 2009
- xxvii Guimaraes and all, Effects of Oropharyngeal Exercises on Patients with Moderate Obstructive Sleep Apnea Syndrome, *American Journal of Respiratory and Critical Care Medicine*, 2009
- xxviii Smithpeter, J and Covell, Jr, Relapse of anterior open bites treated with orthodontic appliances with and without facial myofunctional therapy, *AMJ Ortho*, May, 2010

Post-test

Claim Your CE Credits

Answer the test in the Continuing Education Answer Sheet and submit it by mail or fax with a processing fee of \$36. We invite you to view all of our CE courses online by going to <http://www.towniecentral.com/Dentaltown/OnlineCE.aspx> and clicking the View All Courses button. To complete the test online: After reading the preceding article, type the following link into your browser and click the button Take Exam: <http://www.towniecentral.com/Dentaltown/OnlineCE.aspx?action=PRINT&cid=135>. Please note: If you are not already registered on www.dentaltown.com, you will be prompted to do so. Registration is fast, easy and of course, free.

1. Some goals of Myofunctional Therapy are:
 - a. Correct dysfunctional oral habits.
 - b. Develop tongue to palate rest position
 - c. Establish a lip seal
 - d. None of the above
 - e. All of above
2. Some things to look for in the diagnosis of oral facial myofunctional disorders would be:
 - a. Short upper lip
 - b. Open bite with the tongue between the teeth at rest
 - c. Facial grimace during the swallow
 - d. None of the above
 - e. All of the above
3. Two noxious habits a myofunctional therapist could help with would be:
 - a. Thumb sucking and nail biting
 - b. Drinking alcohol excessively
 - c. Not sleeping well
 - d. Leg tapping
 - e. Being late all the time
4. What could happen to the hard palate when the tongue rests low in the oral cavity?
 - a. A cleft palate develops
 - b. Cancer or other oral lesions develop
 - c. A collapsed palate could lead to a unilateral or bilateral cross-bite
 - d. The patient becomes a nail biter
 - e. Dental decay is prevalent
5. What are some etiologic factors of orofacial myofunctional disorders?
 - a. Sucking habits
 - b. Mouth breathing
 - c. Tongue thrusting
 - d. All of the above
 - e. None of the above
6. Why is it important to check lingual frenum attachments?
 - a. The infant is not able to breast feed properly
 - b. Because this can lead to a low tongue rest posture
 - c. The patient can't swallow correctly
 - d. None of the above
 - e. All of the above
7. What stomach symptoms might be related to orofacial dysfunction?
 - a. Gas and burping
 - b. Hiccups
 - c. Stomach aches
 - d. None of the above
 - e. All of the above
8. Why is sleep position sometimes a factor to attain success in treating oral myofunctional disorders?
 - a. Patient sometimes blocks their airway when they stomach sleep and sometimes TMD develops from shifting their jaw
9. How can orofacial myofunctional therapy help your practice?
 - a. Avoid ortho relapse
 - b. Patients appreciate pro-active treatment
 - c. Eliminates the tongue from blocking your field of vision
 - d. All of the above
 - e. None of the above
10. Why should orofacial myofunctional therapy be part of the dental team?
 - a. Because oral myofunctional therapy stops cavities
 - b. People can hear better after therapy
 - c. Because the patients' vision improves with myofunctional therapy
 - d. Because we can assist the orthodontist and general dentist in assuring them that the muscle patterns are functioning correctly with the bones and teeth

Legal Disclaimer: The CE provider uses reasonable care in selecting and providing content that is accurate. The CE provider, however, does not independently verify the content or materials. The CE provider does not represent that the instructional materials are error-free or that the content or materials are comprehensive. Any opinions expressed in the materials are those of the author of the materials and not the CE provider. Completing one or more continuing education courses does not provide sufficient information to qualify participant as an expert in the field related to the course topic or in any specific technique or procedure. The instructional materials are intended to supplement, but are not a substitute for, the knowledge, expertise, skill and judgment of a trained healthcare professional. You may be contacted by the sponsor of this course.

Licensure: Continuing education credits issued for completion of online CE courses may not apply toward license renewal in all licensing jurisdictions. It is the responsibility of each registrant to verify the CE requirements of his/her licensing or regulatory agency.

Continuing Education Answer Sheet

Instructions: To receive credit, complete the answer sheet and mail it, along with a check or credit card payment of \$36 to: Dentaltown.com, Inc., 9633 S. 48th Street, Suite 200, Phoenix, AZ 85044. You may also fax this form to 480-598-3450. You will need a minimum score of 70% to receive your credits. **Please print clearly. Deadline for submission of answers is 24 months after the publication date. Your certificate will be mailed to you within 3-4 weeks.**

Orofacial Myofunctional Therapy – The Critical Missing Element to Complete Patient Care by Joy Moeller, BS, RDH, COM

License Number _____

AGD# _____

Name _____

Address _____

City _____ State _____ ZIP _____

Daytime phone _____

E-mail (optional) _____

Check (payable to Dentaltown.com, Inc.)

Credit Card (please complete the information below and sign; we accept Visa, MasterCard and American Express.)

Card Number _____

Expiration Date – Month / Year _____ / _____

Signature _____ Date _____

Yes, I would like to continue receiving *Denaltown Magazine* free of charge
(Signature required for subscription - free to U.S. only)

No, thank you.

Program Evaluation (required)

Please evaluate this program by circling the corresponding numbers: (3 = Excellent to 1 = Poor)

- | | | | |
|---|---|---|---|
| 1. Course objectives were consistent with the course as advertised | 3 | 2 | 1 |
| 2. Course material was up-to-date, well-organized and presented in sufficient depth | 3 | 2 | 1 |
| 3. Instructor demonstrated a comprehensive knowledge of the subject | 3 | 2 | 1 |
| 4. Overall, I would rate this course | 3 | 2 | 1 |
| 5. Overall, I would rate this instructor | 3 | 2 | 1 |

For questions, contact Rita Zakher, DMD, MBA, director of continuing education at rita@dentaltown.com

CE Post-test

Please circle your answers.

1. a b c d e
2. a b c d e
3. a b c d e
4. a b c d e
5. a b c d e
6. a b c d e
7. a b c d e
8. a b c d e
9. a b c d e
10. a b c d

Field of practice (optional)

- | | |
|---|---|
| <input type="checkbox"/> General Dentist | <input type="checkbox"/> OMS Resident |
| <input type="checkbox"/> Anesthesiology | <input type="checkbox"/> Oral Pathology |
| <input type="checkbox"/> Consultant | <input type="checkbox"/> Orthodontics |
| <input type="checkbox"/> Cosmetic Dentistry | <input type="checkbox"/> Orthodontic Resident |
| <input type="checkbox"/> Dental Assistant | <input type="checkbox"/> Pediatric Dentistry |
| <input type="checkbox"/> Dental Company Rep. | <input type="checkbox"/> Pediatric Resident |
| <input type="checkbox"/> Dental Education | <input type="checkbox"/> Periodontics |
| <input type="checkbox"/> Dental Lab Tech | <input type="checkbox"/> Periodontic Resident |
| <input type="checkbox"/> Dental Student | <input type="checkbox"/> Prosthodontics |
| <input type="checkbox"/> Dental Hygiene Student | <input type="checkbox"/> Public Health |
| <input type="checkbox"/> Endodontics | <input type="checkbox"/> Radiology |
| <input type="checkbox"/> Endodontic Resident | <input type="checkbox"/> Speaker |
| <input type="checkbox"/> Front Office | <input type="checkbox"/> TMD Specialist |
| <input type="checkbox"/> Hygienist | <input type="checkbox"/> Other |
| <input type="checkbox"/> Implantology | |
| <input type="checkbox"/> Oral & Maxillofacial Surgeon | |