

# Injection of autologous micro-fragmented adipose tissue for the treatment of post-traumatic degenerative lesion of knee cartilage: a case report

M. Franceschini, C. Castellaneta, G. Mineo

Orthopaedic and Trauma Department, Istituto Ortopedico "G. Pini", University of Milan, Milan, Italy

Corresponding Author: Massimo Franceschini, MD; e-mail: massimo.franceschini@gpini.it

**Keywords:** Lipogems®, Cartilage, Micro-fragmented adipose tissue, MSCs, Chondral lesion, Adipose-derived stem cells (ADSC).

## ABSTRACT

**Background:** The chondral lesion of the knee represents a challenge for the orthopedic surgeon because of the limited regenerative properties of the affected tissue. A variety of treatments has been proposed with variable success rates. Recently, new therapeutic approaches, such as the use of mesenchymal stem cells (MSCs), seem to have promising results when applied in the context of joint degeneration, and an ideal source could be the adipose tissue, due to its abundance, the easy access, and the simple isolation procedures.

**Objective:** To evaluate the potential benefits of injecting autologous, micro-fragmented, and minimally manipulated adipose tissue (Lipogems®) in a severe case of a multi-operated cartilage degeneration.

**Case description:** The patient is a 33 years-old man, semi-professional snowboarder, with a knee trauma due to a ski fall who has failed a number of treatments. The patient was injected with Lipogems® and followed up for 30 months.

**Patients and Methods:** Micro-fragmented adipose tissue was obtained using a minimal manipulation technique in a closed system (Lipogems®), without the addition of enzymes or any other additives.

**Results:** After a first period of worsening of pain, symptoms got progressively better, and the pain completely disappeared in 6 weeks. The Oxford Knee Score at 12 weeks improved from 36 (baseline) to 46. The clinical improvement was confirmed by the MRI at 12 months. Thirty months after Lipogems® treatment the patient was able to ski with no pain and no restrictions.

**Conclusion:** Although this is a single case report, our results suggest that the autologous, micro-fragmented and minimally manipulated adipose tissue injected in a joint affected by a chondral lesion provides support and potential healing, improves joint functionality and determines pain relief.

## INTRODUCTION

The chondral lesion of the knee represents a challenge for the orthopedic surgeon because of the limited regenerative properties of the affected tissue. A variety of treatments has been proposed (autologous graft, micro-fractures, physical stimulation, biomaterials, etc.) with variable success rates. Recently, new therapeutic approaches, such as the use of mesenchymal stem cells (MSCs), seem to show promising preliminary results when applied in the context of joint degeneration compared to the poor results obtained with mature chondrocytes<sup>1,2</sup>.

MSCs have extensive proliferative ability in culture in an uncommitted state while retaining their multilineage differentiation potential, which makes them attractive candidates for biological cell-based tissue repair approaches. Initial efforts concentrated on bone marrow-derived MSCs<sup>3</sup>. The controversial and often poorly understood roles of MSCs are slowly being elucidated and the regenerative capabilities of fat (adipose derived stem cells, ADSCs), with mesenchymal properties, are being widely explored<sup>4-7</sup>. The use of MSCs, either expanded or simply obtained by enzymatic treatment as SVF, created a huge interest in the context of cartilage regeneration<sup>8</sup>. Both *in vitro* and *in vivo* studies clearly demonstrated their anti-inflammatory and regenerative potentials<sup>4-6</sup>. Nevertheless, these techniques have complex regulatory issues, and often lead to clinical results below expectations. Hence, availability of a minimally manipulated, autologous adi-

pose tissue would have remarkable biomedical and clinical relevance. For this reason, a new device, named Lipogems<sup>®</sup>, has been developed<sup>9</sup>. The technique is gentle and intra-operatively provides micro-fragmented adipose tissue in a short time (15-20 minutes), without expansion and/or enzymatic treatment<sup>10</sup>, very rich in mature pericytes and MSCs<sup>9,11-13</sup> and which has been shown to be effective in the treatment of different pathologies<sup>14-19</sup>.

Our intention is to show how autologous, micro-fragmented, and minimally manipulated adipose tissue obtained with the new device Lipogems<sup>®</sup>, provides support and potential healing in a severe case of a multi-operated cartilage degeneration in a young adult.

### CASE DESCRIPTION

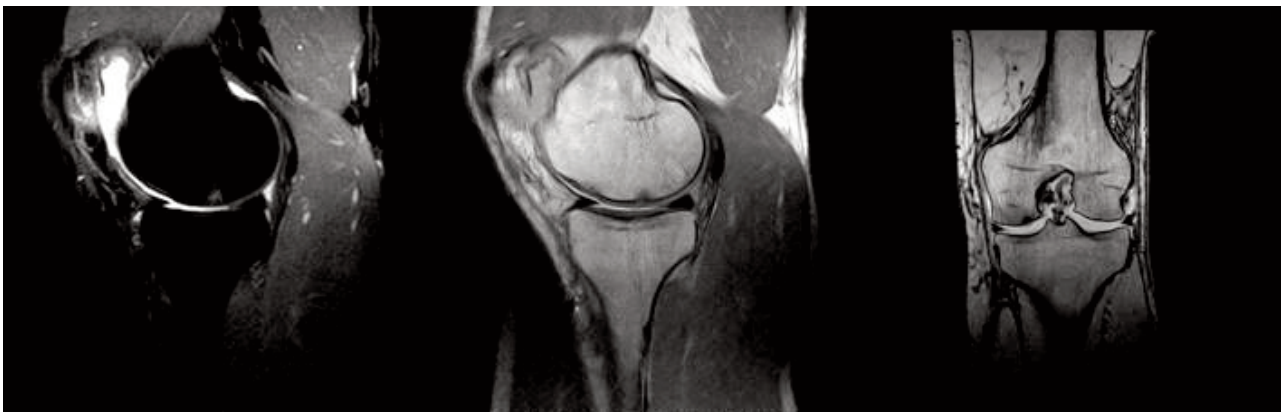The patient is a 33 years-old man, semi-professional snowboarder, with a knee trauma due to a ski fall 3 months before coming to our observation in April 2011. The patient complained for an anteromedial knee pain and instability (especially when walking downstairs) due to an ACL insufficiency. The MRI confirmed the ACL tear and two chondral lesions on the patella and the medial femoral condyle, possibly due to the direct trauma (Figure 1). The arthroscopic evaluation allowed to clearly identify the ACL lesion as partial (antero-medial bundle) but non-functional and to classify the two chondral lesions on the patella and the femoral condyle as Outerbridge grade 2-3.

The patient underwent anterior bundle ACL reconstruction using ipsilateral hamstring tendon autograft. The chondral lesions were treated with microfractures. The postoperative course was normal, the patient was non-weight bearing for 6 weeks

with a flexion limit of 40°. Subsequently, he underwent the normal rehabilitation protocol for ACL reconstruction reaching a full recovery, as expected. The patient resumed common daily activities in about 3 months, nevertheless complaining of constant episodes of anterior knee pain. After 8 months he fully recovered except for a weakness of the thigh muscles (especially the quadriceps) when withstanding isotonic loads. An MRI control 8-months after surgery showed the persistence of chondral lesions on both the patella and femoral condyle.

Because of the continuous pain and the impossibility to perform any sport, a new surgical treatment was suggested. Therefore, the patient underwent a second arthroscopy 10 months after the previous surgery. The new arthroscopic examination enabled to assess the state of the cartilage and the effectiveness of the previous treatment. The chondral lesions were unchanged in terms of area. A thin layer of fibrotic tissue covered three-quarters of the extension, but visually and mechanically insufficient as a simple scraping with the arthroscopic hook was sufficient to remove it. Therefore, we decided to remove this biologically inactive tissue by a shaving procedure and to inject autologous PRP.

The patient was discharged the same day, with the prescription of a period of relative rest and protected weight bearing for about 10 days. At 2 weeks, the patient resumed usual activities, including sports, but, 3 months after, was selected for a single injection of autologous micro-fragmented adipose tissue (Lipogems<sup>®</sup>) because of the persistence of pain and the unsatisfactory results. No restrictions of activity nor rehabilitation protocol after Lipogems<sup>®</sup> treatment were done for this patient, which was treated as an outpatient. Full weight bearing and walking was permitted.



**Figure 1.** Chondral lesion in the medial femoral condyle after knee trauma. In both STIR and T2 weighted sequences it's well documented a focal chondral lesion (Outerbridge 3) with subchondral edema.

## PATIENT AND METHODS

### HARVESTING OF THE ADIPOSE TISSUE

The lower or the lateral abdomen were chosen as donor sites for adipose tissue harvesting. Before harvesting the fat, the selected site was injected with local anesthesia and adrenaline at high dilution using a disposable 17G blunt cannula connected to a Luer lock 60 cc syringe (Figure 2A). The fat was then harvested (72 cc) using a 13G blunt cannula, for a fast and atraumatic suction, connected to a Vaclock 20 ml syringe (Figure 2B).

### PROCESSING OF THE ADIPOSE TISSUE WITH LIPOGEMS® DEVICE

The harvested fat was immediately processed in the 60cc Lipogems® processing kit (Figure 3), a disposable device that progressively reduces the size of the adipose tissue clusters while eliminating oily substances and blood residues which have pro-inflammatory properties. The entire process, carried out in one surgical step, is performed in complete immersion in physiological solution minimizing

any traumatic action on cell products. The Lipogems® tissue was collected in a 60 cc syringe and positioned to decant the excessive saline solution. The product is transferred in several 1 cc syringes to be re-injected in the patient.

### LIPOGEMS® INJECTION

The Lipogems® tissue was injected in the joint and suprapatellar bursa.

### OUTCOME MEASURES

Clinical outcomes were determined using the Oxford Knee Score (OKS) taken at baseline, 10 days, 6 weeks, 3, 12, and 30 months follow-up and a 12 months MRI.

### RESULTS

After a first period (approximately 10 days) of worsening of pain, symptoms got progressively better and the pain completely disappeared in 6 weeks.

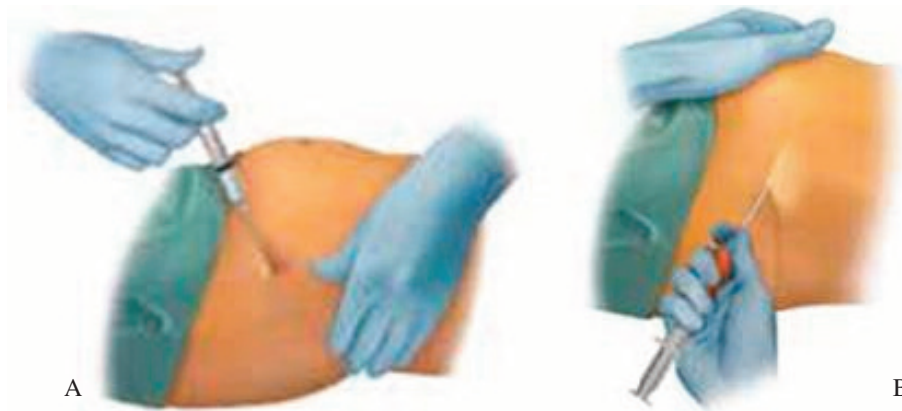

Figure 2. A-B, Harvesting of adipose tissue.

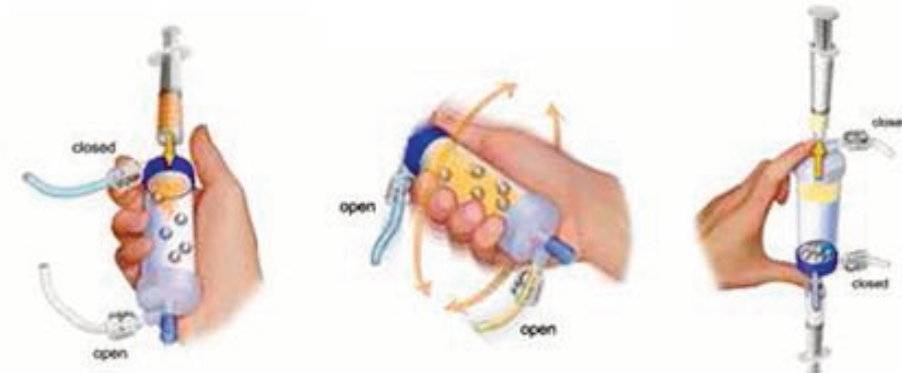


Figure 3. Processing Lipogems.

**Table 1.** Oxford knee score.

	Baseline	10 days	6 weeks	3 months	12 months	30 months
OKS	36	32	46	44	47	48

The OKS at 10 weeks improved from 36 (baseline) to 46 (Table 1). The MRI at 12 months demonstrated an improvement of the signal of the cartilage lesion (Figure 4).

Twelve months after Lipogems<sup>®</sup> injection the patient was still with no pain and the clinical situation was stable and permanently good with a full recovery. The patient returned to his sports activities with no restrictions (OKS 47). Thirty months after Lipogems<sup>®</sup> treatment the patient was still able to ski with no pain and no restrictions.

#### DISCUSSION AND CONCLUSION

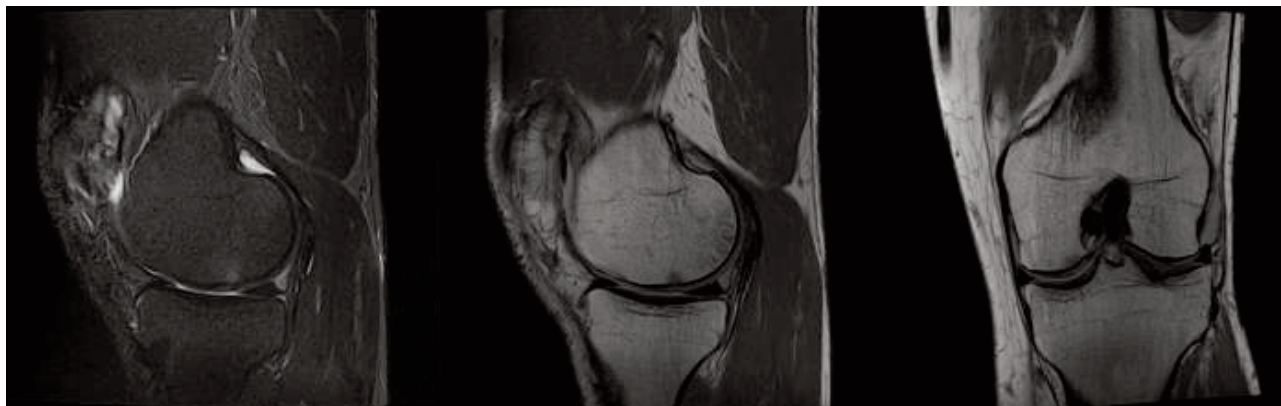
Human adult MSCs have been isolated from many different tissues, such as bone marrow, placenta, dental pulp and, of course, adipose tissue. Among these sources, adipose tissue presents some advantages, like the easy access and the simple isolation procedures. In addition, adipose derived stem cell (ADSC) are very abundant and their number and multipotency do not decrease with age<sup>7,20,21</sup>.

In the last few years, it has been shown the potential benefit of using ADSC in many medical fields such as plastic surgery, gynecology, urology, wound healing, and colonproctology<sup>3,4</sup>. More recently, the scientific community showed an increasing interest in the use of these cells for the treatment of chondral lesions<sup>8,14</sup>.

Up to now, microfractures, Autologous Matrix Induced Chondrogenesis (AMIC) and Matrix Induced Chondrocyte Implantation (MACI) techniques have been considered the gold standard for the treatment of circumscribed chondral lesions. Some of them are partially demolitive on the affected joint; some others need a second surgery after a few time. All of them need a particular rehabilitation with no weight-bearing, have contraindications and high rate of failure<sup>22-30</sup>.

In our case, microfractures were not enough to treat the chondral lesions. The thin layer of fibrotic tissue seen in the second arthroscopy was biomechanically insufficient and the patient was not able either to perform his sports activities, nor to have a pain-free life.

The injection of autologous micro-fragmented adipose tissue caused an initial worsening of the situation, probably due to a weak inflammatory response after the injection. Then, the clinical situation started to improve, and, after 12 weeks, the Oxford Knee Score was significantly better. The patient was able to walk and run without pain and to ski with minimum pain. MRI images at 12 months showed a clear improvement of the signal of the cartilage injury, confirming our clinical evaluation. After 30 months, the patient was totally satisfied, indicating no pain and recovered complete range of motion.



**Figure 4.** At 12 months follow-up after Lipogems injection the MRI confirms the formation of a layer of new fibrous cartilage which totally covers the defect. The regression of subchondral edema, even if incomplete, is significant and correlates with the reduction of knee pain and with clinical improvements.



Although this is a single case report, our results suggest that the autologous, micro-fragmented and minimally manipulated adipose tissue (Lipogems®) injected in a joint affected by a chondral lesion provides support and potential healing, improves joint functionality and determines pain relief<sup>31</sup>. Moreover, weight-bearing is allowed immediately after the surgery and no particular rehabilitation is required. No contraindications or adverse events have been described in the literature for this procedure nor observed in our case. All of these features point to Lipogems® as a safe, cost-effective, and repeatable system for the treatment of chondral lesions. Despite our very promising results, more studies are required to validate its efficacy on a larger scale.

## REFERENCES

- Dhollander AAM, Verdonk PCM, Lambrecht S, Verdonk R, Elewaut D, Verbruggen G, Almqvist KF. Midterm results of the treatment of cartilage defects in the knee using alginate beads containing human mature allogenic chondrocytes. *Am J Sports Med* 2012; 40(1): 75-82.
- Almqvist KF, Dhollander AAM, Verdonk PCM, Forsyth R, Verdonk R, Verbruggen G. Treatment of cartilage defects in the knee using alginate beads containing human mature allogenic chondrocytes. *Am J Sports Med* 2009; 37(10): 1920-1929.
- Tremolada C, Palmieri G, Ricordi C. Adipocyte transplantation and stem cells: plastic surgery meets regenerative medicine. *Cell Transplant* 2010; 19(10): 1217-1223.
- Banyard DA, Salibian AA, Widgerow AD, Evans GR. Implications for human adipose-derived stem cells in plastic surgery. *J Cell Mol Med* 2015; 19(1): 21-30.
- Chang KA, Lee JH, Suh YH. Therapeutic Potential of Human Adipose-Derived Stem Cells in Neurological Disorders. *J Pharm Sci* 2014; 126(4): 293-301.
- Jia HY, Yu JH, Lei TC. The multi-lineage differentiation and angiogenesis ability of adipose-derived adult mesenchymal stem cells. *Clin Lab* 2014; 60(10): 1747-1755.
- Awad HA, Wickham MQ, Leddy HA, Gimble JM, Guilak F. Chondrogenic differentiation of adipose-derived adult stem cells in agarose, alginate, and gelatin scaffolds. *Biomaterials* 2004; 25(16): 3211-3222.
- Ruetze M, Richter W. Adipose-derived stromal cells for osteoarticular repair: trophic function versus stem cell activity. *Expert Rev Mol Med* 2014; 9,16: e9.
- Bianchi F, Maioli M, Leonardi E, Olivi E, Pasquinelli G, Valente S, Mendez AJ, Ricordi C, Raffaini M, Tremolada C, Ventura C. A new nonenzymatic method and device to obtain a fat tissue derivative highly enriched in pericyte-like elements by mild mechanical forces from human lipoaspirates. *Cell Transplant* 2013; 22(11): 2063-2077.
- Maioli M, Rinaldi S, Santaniello S, Castagna A, Pigliaru G, Delitala A, Bianchi F, Tremolada C, Fontani V, Ventura C. Radioelectric asymmetric conveyed fields and human adipose-derived stem cells obtained with a nonenzymatic method and device: a novel approach to multipotency. *Cell Transplant* 2014; 23(12): 1489-1500.
- Carelli S, Messaggio F, Canazza A, Hebda DM, Caremoli F, Latorre E, Grimoldi MG, Colli M, Bulfamante G, Tremolada C, Di Giulio AM, Gorio A. Characteristics and properties of mesenchymal stem cells derived from micro-fragmented adipose tissue. *Cell Transplant* 2014; 24: 1233-1252.
- Garcia-Contreras M, Messaggio F, Jimenez O, Mendez A. Differences in exosome content of human adipose tissue processed by non-enzymatic and enzymatic methods. *CellR4* 2014; 3(1): e1423.
- Canaider S, Maioli M, Facchin F, Bianconi E, Santaniello S, Pigliaru G, Ljungberg L, Burigana F, Bianchi F, Olivi E, Tremolada C, Biava PM, Ventura C. Human stem cell exposure to developmental stage zebrafish extracts: a novel strategy for tuning stemness and senescence patterning. *CellR4* 2014; 2(5): e1226.
- Striano RD, Chen H, Bilbool N, Azatullah K, Hilado J, Horan K. Non-responsive knee pain with osteoarthritis and concurrent meniscal disease treated with autologous micro-fragmented adipose tissue under continuous ultrasound guidance. *CellR4* 2015; 3(5): e1690.
- Benzi R, Marfia G, Bosetti M, Beltrami G, Magri AS, Versari S, Tremolada C. Microfractured lipoaspirate may help oral bone and soft tissue regeneration: a case report. *CellR4* 2015; 3(3): e1583.
- Giori A, Tremolada C, Vailati R, Navone SE, Marfia G, Caplan AI. Recovery of function in anal incontinence after micro-fragmented fat graft (Lipogems®) injection: two years follow up of the first 5 cases. *CellR4* 2015; 3(2): e1544.
- Cestaro G, De Rosa M, Massa S, Amato B, Gentile M. Intersphincteric anal lipofilling with micro-fragmented fat tissue for the treatment of faecal incontinence: preliminary results of three patients. *Wideochir Inne Tech Maloinwazyjne* 2015; 10(2): 337-341.
- Raffaini M, Tremolada C. Micro fractured and purified adipose tissue graft (Lipogems®) can improve the orthognathic surgery outcomes both aesthetically and in postoperative healing. *CellR4* 2014; 2(4): e1118.
- Bianchi F, Olivi E, Baldassarre M, Giannone FA, Laggetta M, Valente S, Cavallini C, Tassinari R, Canaider R, Pasquinelli G, Tremolada C, Ventura C. Lipogems, a new modality of fat tissue handling to enhance tissue repair in chronic hind limb ischemia. *CellR4* 2014; 2(6): e1289.
- De Ugarte DA, Morizono K, Elbarbary A, Alfonso Z, Zuk PA, Zhu M, Dragoo JL, Ashjian P, Thomas B, Benhaim P, Chen I, Fraser J, Hedrick MH. Comparison of multi-lineage cells from human adipose tissue and bone marrow. *Cells Tissues Organs* 2003; 174(3): 101-109.
- Huang JI, Zuk PA, Jones NF, Zhu M, Lorenz HP, Hedrick MH, Benhaim P. Chondrogenic potential of multipotential cells from human adipose tissue. *Plast Reconstr Surg* 2004; 113(2): 585-594.
- Seo SS, Kim CW, Jung DW. Management of focal chondral lesion in the knee joint. *Knee Surg Relat Res* 2011; 23(4): 185-196.
- Ulstein S, Årøen Ar, Røtterud JH, Løken S, Engebretsen L, Heir S. Microfracture technique versus osteochondral autologous transplantation mosaicplasty in patients with articular chondral lesions of the knee: a prospective randomized trial with long-term follow-up. *Knee Surg Sports Traumatol Arthrosc* 2014; 22(6): 1207-1215.

24. Williams 3<sup>rd</sup> RJ, Harnly HW. Microfracture: indications, technique, and results. *Instr Course Lect* 2006; 56: 419-428.
25. Behery O, Siston RA, Harris JD, Flanigan DC. Treatment of cartilage defects of the knee: expanding on the existing algorithm. *Clin J Sport Med* 2014; 24(1): 21-30.
26. Harris JD, Brophy RH, Siston RA, Flanigan DC. Treatment of chondral defects in the athlete's knee. *Arthroscopy* 2010; 26(6): 841-852.
27. Tetteh ES, Bajaj S, Ghodadra NS, Cole BJ. The basic science and surgical treatment options for articular cartilage injuries of the knee. *J Orthop Sports Phys Ther* 2012; 42(3): 243-253.
28. Dhollander AA, Guevara Sanchez VR, Almqvist KF, Verdonk R, Verbruggen G, Verdonk PC. The use of scaffolds in the treatment of osteochondral lesions in the knee: current concepts and future trends. *J Knee Surg* 2012; 25(3): 179-186.
29. Zorzi C, Dall'Oca C, Cadossi R, Setti S. Effects of pulsed electromagnetic fields on patients' recovery after arthroscopic surgery: prospective, randomized and double-blind study. *Knee Surg Sports Traumatol Arthrosc* 2007; 15(7): 830-834.
30. Fini M, Giavaresi G, Carpi A, Nicolini A, Setti S, Giardino R. Effects of pulsed electromagnetic fields on articular hyaline cartilage: review of experimental and clinical studies. *Biomed Pharmacother* 2005; 59(7): 388-394.
31. Bosetti M, Borrone A, Follenzi A, Messaggio F, Tremolada C, Cannas M. Human lipoaspirate as autologous injectable active scaffold for one-step repair of cartilage defects. *Cell Transplant* 2015; Epub ahead of print.