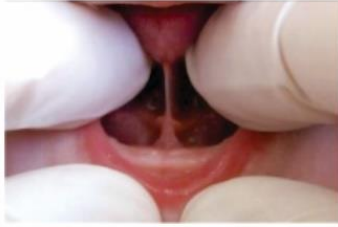

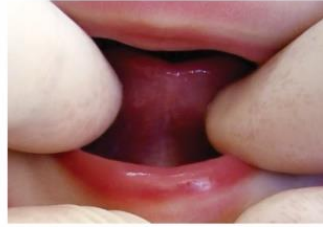LINGUAL FRENULUM PROTOCOL FOR INFANTS

Martinelli, 2015

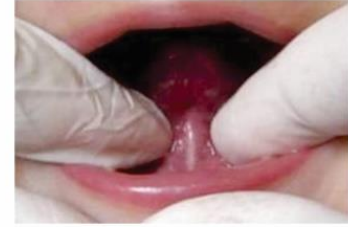4. Lingual Frenulum



() visible



() not visible

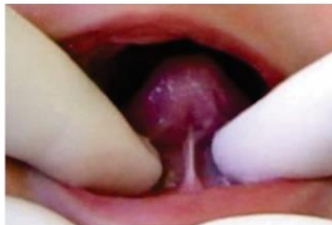

() visible with maneuver*

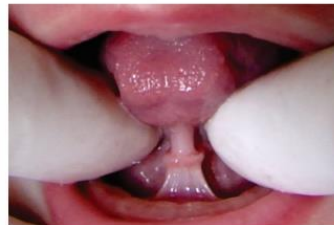*Maneuver: elevate and push back the tongue.

If the frenulum is not visible, go to PART II (Non-nutritive sucking and nutritive sucking evaluations)

4.1. Frenulum thickness

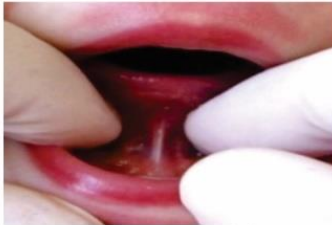

() thin (0)

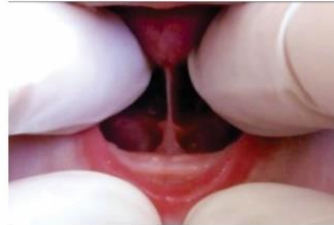

() thick (2)

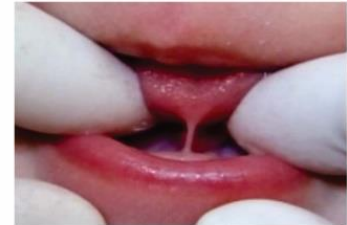4.2. Frenulum attachment to the tongue



() midline (0)

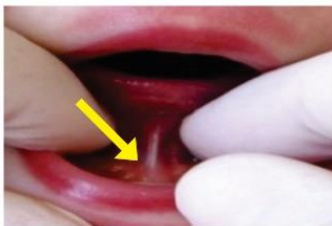

() between midline and apex (2)

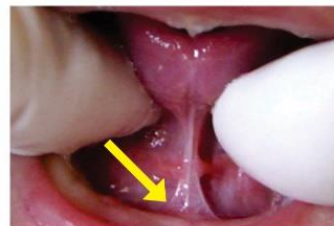


() apex (3)

4.3. Frenulum attachment to the floor of the mouth



() visible from the
sublingual caruncles (0)



() visible from the
inferior alveolar crest (1)

Anatomo-functional evaluation total score (items 1,2, 3 and 4): Best result=0 Worst result=12

When the score of items 1, 2, 3 and 4 of the anatomo-functional evaluation is equal or greater than 7, the interference of the frenulum with the movements of the tongue may be considered. Release of lingual frenulum is indicated.

LINGUAL FRENULUM PROTOCOL FOR INFANTS

Martinelli, 2015

PART II – EVALUATION OF NON-NUTRITIVE SUCKING AND NUTRITIVE SUCKING

1. Non-nutritive sucking (little finger sucking wearing gloves)

1.1. Tongue movement

- adequate: coordinated movement (0)
- inadequate: restricted tongue anteriorization, uncoordinated movements and sucking delay (1)

2. Nutritive sucking during breastfeeding

(when breastfeeding starts, observe infant sucking during five minutes)

2.1. Sucking Rhythm (observe groups of sucking and pauses)

- several suckings in a row followed by short pauses (0)
- a few suckings followed by long pauses (1)

2.2. Coordination among sucking/ swallowing/ breathing

- adequate (0) (balance between feeding efficiency and sucking, swallowing and breathing functions without stress)
- inadequate (1) (cough, choking, dyspnea, regurgitation, hiccup, swallowing noises)

2.3. Nipple chewing

- no (0)
- yes (1)

2.4. Clicking during sucking

- no (0)
- yes (1)

Non-nutritive sucking and nutritive sucking total score: Best result= 0 worst= 5

HISTORY AND CLINICAL EXAMINATION TOTAL SCORES: Best result= 0 Worst result= 25

Sum of the CLINICAL EXAMINATION scores (anatomy-functional evaluation and non-nutritive sucking and nutritive sucking):
Scores 0 - 8: there is no interference of lingual frenulum with tongue movements ()
Scores 9 or more: there is interference of the lingual frenulum with tongue movements. ()
Release of lingual frenulum is indicated.

Sum of HISTORY and CLINICAL EXAMINATION scores
Scores 0 -12: there is no interference of lingual frenulum with tongue movements ()
Scores 13 or more: there is interference of the lingual frenulum with tongue movements. ()
Release of lingual frenulum is indicated.