

BIG success

External tissue expander can augment size, vascularity of recipient space to allow large-volume lipografting

Cheryl Guttman Krader

SENIOR STAFF CORRESPONDENT

Megavolume lipografting, enabled by pregrafting external tissue expansion that creates an enlarged, vascularized recipient space, is a safe and predictably effective approach for breast augmentation, says Roger K. Khouri, M.D.



Dr. Khouri

“Current discussions about improving outcomes of fat transplantation are focusing on methods for atraumatic harvesting, processing and delivery, as well as on the role of stem cells or other

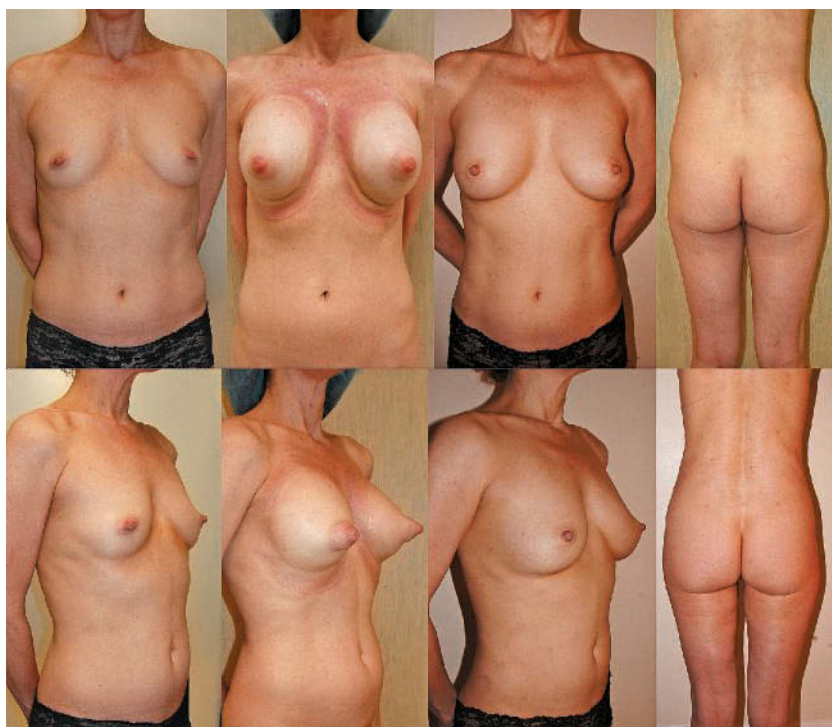adjuncts for optimizing graft survival. However, these discussions are ignoring the importance of optimizing the graft-recipient interface,” says Dr. Khouri, in private practice at the Miami Breast Center, Key Biscayne, Fla.

“Successful fat transplantation requires attention to all of the involved elements because each by itself is a rate-limiting step, and if the goal is to deliver a large-volume graft, the recipient site must be proportionately sized. A farmer who plants a huge number of seeds into a small pot cannot expect to grow a big crop,” he says.

Dr. Khouri says he pioneered this procedure for autologous fat breast augmentation, which uses an external, bra-like, vacuum-based expansion device that he invented (Brava Breast Enhancement and Shaping System, Brava LLC). Here, he discusses the procedure as well as intraoperative and postoperative techniques to optimize graft take and survival.

Dr. Khouri says he developed the concept of external expansion to create an enlarged, vascularized scaffold as the recipient site for fat transplantation in the breast in 2004, at a time





Left: A 35-year-old nulliparous patient with minimal body fat desiring a natural-looking autologous fat breast augmentation. Pre-expansion views (far left images), maximal pre-grafting Brava expansion views (second to left) and one year follow-up result (second to right images); 330 mL of fat were harvested by tumescent liposuction from each flank — pre- (above, far right) and post-liposuction (below, far right) photos show the improved body contour of the donor sites, Dr. Khouri says. Volume measurement from 3D reconstructions of the baseline versus one year follow-up MRI show a 270 mL augmentation per breast and a graft survival of 82 percent. It is the pregrafting expansion of the recipient breast by 370 mL that allowed it to accept this large graft volume without compromising the interstitial pressure, Dr. Khouri says. The increased recipient space also made it possible to diffusely disperse the individual fat droplets and avoid the localized collections that compromise graft to recipient interface. (Photos credit: Roger Khouri, M.D.)

when breast enhancement with autologous fat was considered was looked down upon. Patients are asked to wear the expansion device each night for at least 10 hours for a period of four weeks.

Early on, Dr. Khouri says he undertook a prospective study using 3-D volumetric analysis of serial MRI images to evaluate the effect of the expansion and its effect on the outcome of the fat graft procedure. The results provided proof of concept, he says, showing dose-response relationships between patient compliance with expander wear and increased size and vascularity of the recipient space and between recipient space size and achieved postgraft augmentation volume.

Data collected in a soon-to-be published prospective multicenter study enrolling 81 women (Khouri RK, Eisenmann-Klein M, Cardoso E, et al. *Plast Reconstr Surg.* 2012 Epub ahead of print) show a strong linear correlation between pregrafting recipient site expansion and the breast augmentation volume. Among 71 women who wore the expansion device preoperatively, the mean augmentation volume at 12 months follow-up was 233 mL/breast, representing 82 percent graft survival.

These outcomes are highly significantly different compared with historical controls from published series of women having breast augmentation without pregraft expansion, Dr. Khouri says. "In the women without pregraft expansion, mean augmentation volume at 12 months was

only 134 mL/breast and graft survival only 55 percent," he says.

Dr. Khouri adds that results from the prospective study of megavolume breast augmentation with pregraft expansion also refute the criticism that results of fat grafting for breast augmentation are unpredictable. "According to the linear dose-response curve we established, patients can be told that two-thirds to three-fourths of the volume they achieve with pregraft expansion will become permanent augmentation," he says.

THE WEAKEST LINK Recognizing that the outcome of autologous fat transplantation depends on its weakest link, Dr. Khouri says he has refined his entire technique to maximize the quality of the fat graft, its delivery and postoperative survival. Together with Tom Baker, M.D., and Tom Biggs, M.D., Dr. Khouri has developed a farmer analogy that describes the success of planting as depending on the "four S's" — seeds, soil, sowing and support. For harvesting, he uses a spring-loaded syringe that pulls a constant 300 mm Hg vacuum and special 12-hole cannulas that he says he developed.

"It's intuitive that more fat can be harvested faster using a cannula with a greater number of holes, although there was existing dogma that because of the viscosity of fat, harvesting efficiency reached a plateau using a cannula with three holes. We've proven in a study that the 12-hole cannula allows for increased harvesting efficiency,

The Mini XL

with Prep Resistant Ink

Visible up to 10X longer vs. traditional ink markers after prep.



Ideal for Liposuction Procedures

Traditional Ink



Mini XL Ink



- The Standard for marking patients where prep or fluids remove the surgeon's pre-surgical marks
- XL Prep-Resistant Ink Markers are available in Sterile and Non-Sterile

New!

Oh Sooo Fine!



BlephMarker™

- Perfect for precise facial marking or other fine lines
- Filled with traditional skin marking ink
- Available in Sterile and Non-Sterile

VISCOT™

MEDICAL, LLC.

1.800.221.0658

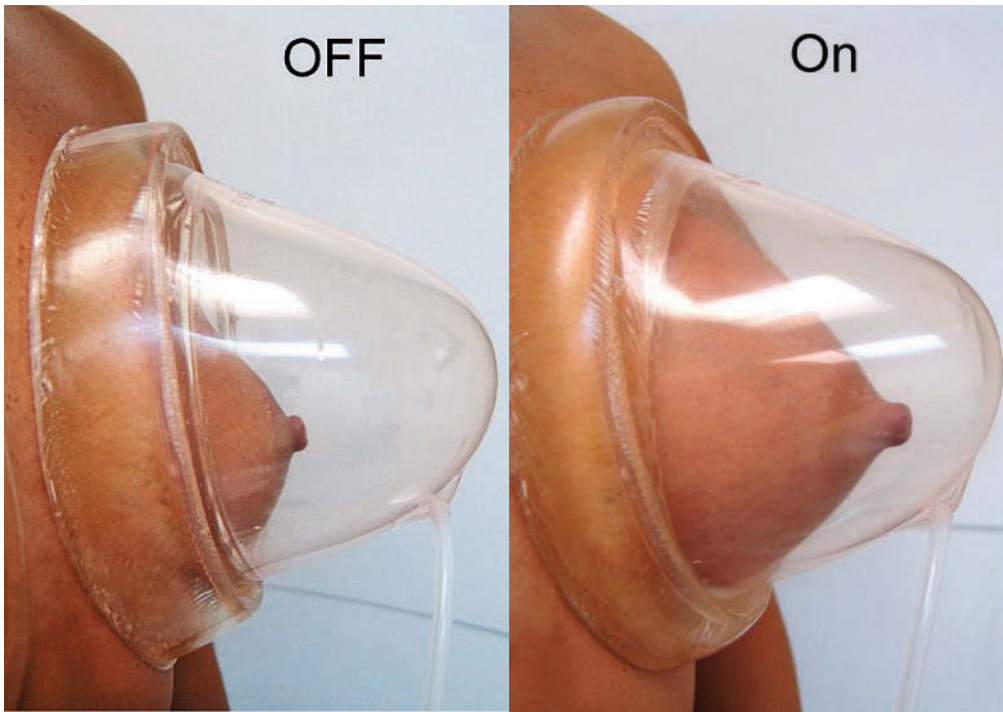




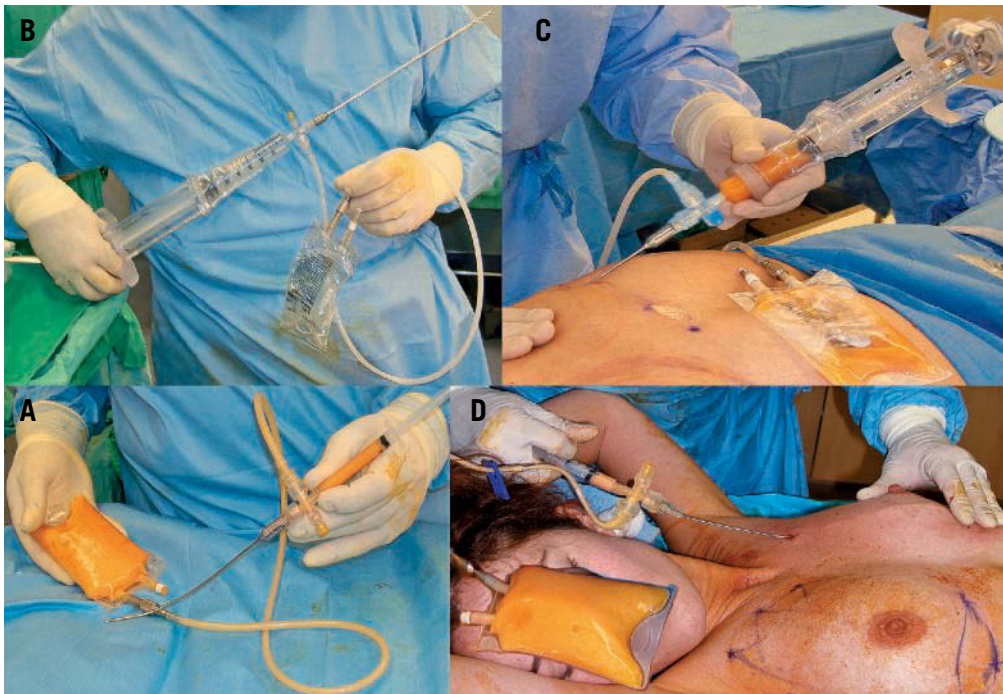
visit www.viscot.com for promotional offer

“If the extracted fat contains little to no blood, it will separate very rapidly with minimal centrifugation. The result of this technique is a slurry-like material.”

Roger K. Khouri, M.D.
Key Biscayne, Fla.



Brava vacuum pressure applies an orthogonal expansion force on the breast to generate the recipient scaffold required for the large volume fat graft. (Photos credit: Roger Khouri, M.D.)



Fat harvesting and grafting with the Lipografter closed system. Clockwise, starting from lower-left — A: A 12-hole, 12-gauge cannula connected to the spring-loaded syringe via the two-way tissue valve with tubing leading to the sterile collection bag; B: Ribbon springs connected to the syringe impart a 300 mm Hg vacuum aspiration force that is constant along the entire excursion of the plunger to gently liposuction the fat into the syringe. Once the syringe is full, pushing the plunger down re-cocks the spring and the valve sends the fat to the collection bag; C: After gentle centrifugation of the bag, the fluid is drained and the fat is concentrated in the collection bag that now becomes the delivery bag. The same valve in reverse mode now draws the fat from the bag to the 3 mL syringe and pushing the plunger down injects it into the tissues. The grafting cannula is a 14-gauge, single-hole, spatulated round tip with a gentle curve to better follow body contour. This system saves the loss of motion associated with switching cannulas and reloading syringes, Dr. Khouri says; D: Fat is grafted through multiple circummammary needle holes, fanning out multiple radial passes through each entry side, preferentially in the subcutaneous preglandular planes while retracting the cannula, to leave behind a thin ribbon wheal. (Photos credit: Roger Khouri, M.D.)

◆ *Megavolume* continued

with the added benefit of lower vacuum compared with a single-hole cannula,” Dr. Khouri says.

Dr. Khouri says he has also devised a closed system (Lipografter, Lipocosm LLC) for atraumatically collecting, processing and grafting that minimizes manipulation of the fat and avoids its exposure to air. Fat withdrawn through the cannulas is transferred into a collection bag via a two-way valve, and once the harvesting is complete, the bag is centrifuged gently at 15 g.

“If the extracted fat contains little to no blood, it will separate very rapidly with minimal centrifugation,” Dr. Khouri says. “The result of this technique is a slurry-like material. Going back to the farmer analogy, the farmer doesn’t plant seeds in clumps, but rather one at a time.”

The sedimented fat is transferred directly to the 3 mL grafting syringes using the same two-way valves in reverse mode. It is delivered to the breast in a 3-D fanning pattern through multiple entry sites (10 to 14) and using a fine cannula attached to the small grafting syringe. These instruments enable precise and diffuse injection, he says.

The injections are periglandular only and particularly target the subcutaneous space. Dr. Khouri says that “gives the most bang for the buck,” but fat is also deposited into and below the pectoralis muscle. The volume delivered is equivalent to the amount of space created by the expansion. Dr. Khouri says he cautions surgeons to be wary of the “last drop effect.”

“Overgrafting is a common cause of failure. If the potential volume of the graft recipient space and its tissue compliance are exceeded, there will be increased interstitial pressure and decreased perfusion that will compromise graft survival. It is all about the container: If it is filled beyond its capacity, it will bust,” he says.

To support the graft after surgery, patients are instructed to wear the external expansion device for one week, beginning 24 hours after surgery. The device acts as a splint, holding open the space from the pregrafting expansion, and any spaces opened from intraoperative contracture release while also stabilizing the grafted fat against movement and subsequent trauma that could compromise its survival, Dr. Khouri says. ◀

Disclosures:

Dr. Khouri is a stockholder of Brava LLC and Lipocosm LLC.