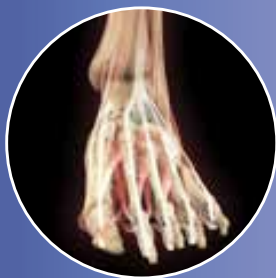
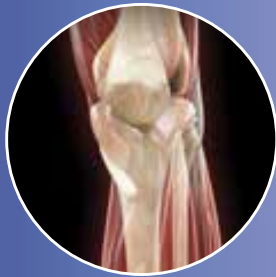
PRP *for*

Treatment

Orthopedics

- Acute Tendon Injuries
- Ligament & Muscle Injuries
- Surgery
- Knee Arthritis
- Fractures

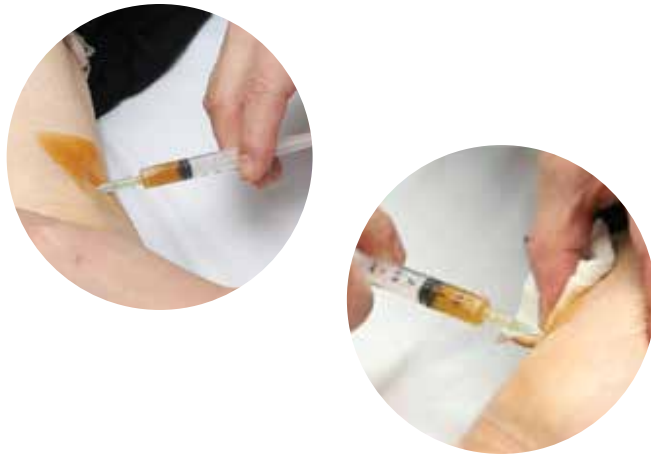

Non-Surgical Regenerative Therapy Using Autologous Blood

A Bioactive Cellular Treatment for Orthopedics
with Platelet-derived Growth Factors.

Anterior Cruciate Ligament Grafts With and Without PRP

ACL reconstruction with the use of PRPG achieves complete homogeneous grafts assessed by MRI, in 179 days compared with 369 days for ACL reconstruction without PRPG. This represents a time shortening of 48% with respect to ACL reconstruction without PRPG.¹⁾



PRP Improves Chronic Tendinosis

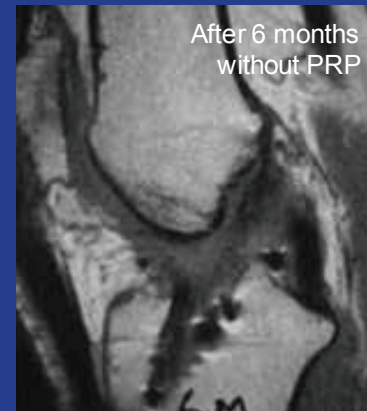
PRP may improve tendon injuries as well as other chronic tendinosis. Specifically, it could be possible to treat an acute Achilles tendon tear non-operatively using a PRP injection.²⁾

Non-surgical, ultrasound guided injection of PRP into the Achilles tendon within one month of injury, significantly improved a 90% Achilles tendon rupture in 6 weeks, leaving only a small focal tear. At 24 weeks, the tear was completely resolved.³⁾

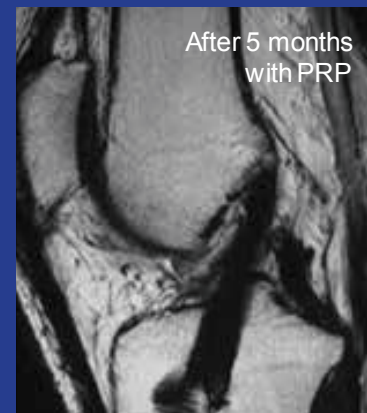Reference

- 1) Radice F, et al, Comparison of Magnetic Resonance Imaging Findings in Anterior Cruciate Ligament Grafts with and without Autologous Platelet-derived Growth Factors, *The Journal of Arthroscopic and Related Surgery* 26, issue 1, 2010;50-57
- 2) Mishra, et al, Treatment of Tendon and Muscle Using Platelet-Rich Plasma, *Clin Sports Med* 28, 2009;113-125
- 3) Steven Sampson, et al, Platelet-rich Plasma Therapy as a first-line Treatment for severe Achilles Tendon Tear: a case report, *International Journal of Therapy and Rehabilitation* 18, 2011;101-106
- 4) Wellington K, et al, Platelet-rich Plasma in Orthopaedic Applications: Evidence-based Recommendations for Treatment, *J am Acad Orthop Surg* 21, 2013;739-748

Anterior Cruciate Ligament Grafts With and Without PRP



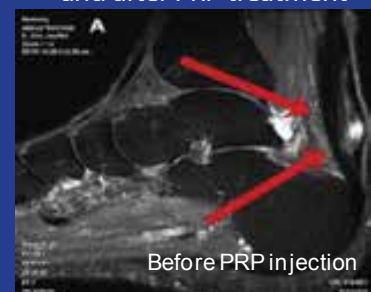After 6 months without PRP



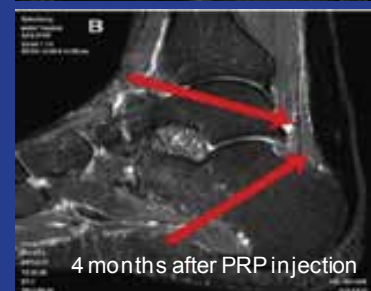After 5 months with PRP

A more homogeneous signal was demonstrated in grafts with PRP, which suggests a quicker maturation rate.⁴⁾

Achilles MRI before and after PRP treatment



Before PRP injection



4 months after PRP injection

Achilles MRI before and after PRP treatment. (A) MRI before PRP injection, partial Achilles tendon tear. (B) MRI 4 month after PRP, healing of partial tear.⁴⁾