

# Favorable Outcomes After Sonographically Guided Intratendinous Injection of Hyperosmolar Dextrose for Chronic Insertional and Midportion Achilles Tendinosis

Michael Ryan<sup>1</sup>  
Anthony Wong<sup>2</sup>  
Jack Taunton<sup>1</sup>

**OBJECTIVE.** The objective of our study was to report on changes in the short-term sonographic appearance and 2-year follow-up for pain outcomes in a large patient population with chronic Achilles tendinosis who underwent sonographically guided dextrose injections.

**SUBJECTS AND METHODS.** One hundred eight tendons (86 midportion and 22 insertional) from 99 patients experiencing pain for greater than 6 months at either the Achilles tendon insertion or midportion were included in the study. Gray-scale (5–12 and 7–15 MHz) and color Doppler sonography examinations preceded the injection procedure using a 27-gauge needle administering a net 25% dextrose–lidocaine solution intratendinously. Structural features of each tendon and presence of neovascularity were noted. Visual analog scale (VAS) items were recorded at baseline, posttest, and 28.6 months follow-up.

**RESULTS.** A median of five (range, 1–13) injection consultations were needed for each patient, spaced  $5.6 \pm 3.1$  (SD) weeks apart. There was a significant improvement in pain scores for both midportion (rest:  $34.1 \pm 27.7$ – $3.3 \pm 7.4$ , activities of daily living (ADL):  $50.2 \pm 25.6$ – $9.5 \pm 16.2$ , and sport:  $70.7 \pm 23.3$ – $16.7 \pm 22.0$ ) and insertional (rest:  $33.0 \pm 26.5$ – $2.7 \pm 6.0$ , ADL:  $51.3 \pm 25.4$ – $10.0 \pm 16.3$ , and sport:  $69.6 \pm 24.5$ – $17.7 \pm 29.1$ ) patients from baseline to follow-up for all VAS items. There were reductions in the size and severity of hypochoic regions and intratendinous tears and improvements in neovascularity.

**CONCLUSION.** Dextrose injections appear to present a low-cost and safe treatment alternative with good long-term evidence for reducing pain from pathology at either the insertion or midportion of the Achilles tendon.

**Keywords:** Achilles tendon, dextrose prolotherapy, interventional radiology, tendinopathy

DOI:10.2214/AJR.09.3255

Received June 18, 2009; accepted after revision October 12, 2009.

Supported by an operating grant from WorksafeBC, the worker's compensation board of British Columbia.

<sup>1</sup>Experimental Medicine Programme, University of British Columbia, Allan McGavin Sports Medicine Centre, John Owen Pavilion, 3055 Westbrook Mall, Vancouver, BC, Canada V6T 1Z3. Address correspondence to M. Ryan (mryan76@gmail.com).

<sup>2</sup>Department of Radiology, University of British Columbia, St. Paul's Hospital, Vancouver, BC, Canada.

AJR 2010; 194:1047–1053

0361–803X/10/1944–1047

© American Roentgen Ray Society

**A**chilles tendinosis is a chronic, degenerative condition affecting both sedentary individuals and athletes of all abilities, with prevalence in running-based sports particularly high [1]. In the general population, the lifetime cumulative incidence of Achilles tendinosis is 5.9% among sedentary people and 50% among elite endurance athletes [2]. In a survey of 2,002 running injuries seen over a 10-year period at a referral sports medicine clinic, overuse injury to the Achilles tendon was the sixth most common injury [3].

Injury to the midportion of the Achilles tendon, typically 2–6 cm proximal to its insertion, is more prevalent than tendon pathology found at the insertion and accounts for approximately 66% of all injuries to the Achilles tendon [4]. Pain is considered to be the primary symptom of Achilles tendinosis, to the extent that it is suggested that a patient's symptoms can reflect the severity of the condition [5]. Often patients describe a

period of tendon pain that is at least partially resolved through either time or a treatment intervention [6]. Unfortunately, symptoms often return with increased and repeated tensile strain as the athlete returns to the preinjury training regimen. This pattern of injury, healing, and reinjury with return to sport is understood to contribute to biochemical changes in the extracellular matrix and degradation in the collagen composition eventually resulting in tissue degeneration and compromised biomechanical properties [7, 8]. Signs of tissue degeneration are observable sonographically with the use of modern high resolution ultrasound transducers and may include intratendinous tearing, changes in tendon echotexture (structural degeneration), neovessel infiltration, intratendinous calcification, and irregularities to bone cortex at the tendon insertion [9, 10].

A previous pilot investigation of injections of hyperosmolar dextrose administered under sonographic guidance reported favorable

outcomes in a population with chronic symptoms [11]. Significant improvements in pain at rest and with activities of daily living as well as during or immediately after sports participation were documented, coupled with improvements in the ultrastructure of the tendon throughout the treatment process. Recently, a similar injection procedure to address pain associated with long-standing plantar fasciitis reported that 16 of the 20 patients investigated were either asymptomatic or at a minimum of 70% pain reduction at 1-year follow-up [12].

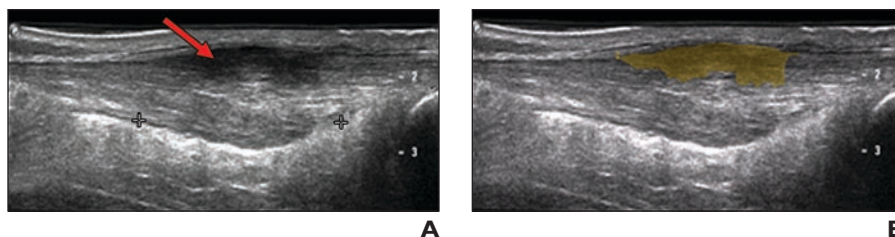
The current study reports the outcomes of pain and sonographically observable structural changes of sonographically guided injections of hyperosmolar dextrose on a large patient population experiencing pain at both the Achilles tendon insertion and midportion. Our outcomes will include our standard assessment of pain at baseline and after final consultation as well as a follow-up duration encompassing 1–4 years posttreatment.

### Subjects and Methods

The diagnosis of Achilles tendinosis was made on the basis of pain directly at the posterior border of the calcaneus or along the midportion of the tendon 2–6 cm proximal to its insertion. All patients in the study group were referred from board-certified sports medicine specialists within the local Vancouver area and must have been unresponsive to the previous conservative treatments prescribed. Treatments included prescribed home-based physiotherapy exercises ( $n = 38$ ), an exercise regimen including eccentric heel drops ( $n = 22$ ), extracorporeal shockwave therapy ( $n = 7$ ), custom foot orthotics ( $n = 5$ ), massage (registered massage therapist) ( $n = 4$ ), prescribed medication (in all cases nonsteroidal antiinflammatory agents) ( $n = 7$ ), and cortisone injections ( $n = 6$ ). Most of the subjects were runners ( $n = 25$ ), with cycling ( $n = 13$ ), tennis ( $n = 10$ ), and hiking ( $n = 10$ ) also listed as activities undertaken on a regular basis. All patients gave informed consent before enrollment and all study protocols received ethical approval from the local university clinical review board.

### Sonography Examination

The sonography examination and the injection procedure were performed by a radiologist with 20 years of experience in musculoskeletal sonography. The Achilles tendon and surrounding tissue were examined with the patient in a prone position. The same examination procedure and sonographic evaluation were performed at each injection consultation. The sonography examination was performed on an HDL 5000 scanner (Philips Healthcare) using both a 5–12 and a 7–15 MHz



**Fig. 1**—Structural changes at Achilles tendon in 55-year-old woman with chronic tendinosis. **A**, Sonogram shows hypoechoic region (arrow). **B**, Sonogram shows freehand measurement tool (shaded area) used to measure area of hypoechoic regions in same tendon.

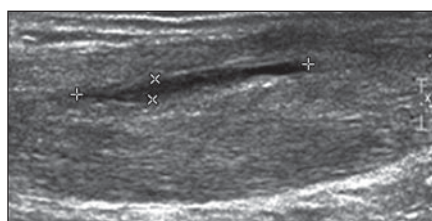
linear-array high-resolution transducer. The tendon in its entirety was examined in the longitudinal and transverse planes, with tendon thickness recorded as the greatest distance spanning the tendon in the anteroposterior plane. Care was taken to image the Achilles tendon parallel with the fibers in the longitudinal plane and perpendicular to the fibers in the transverse plane to avoid artifact such as anisotropy. Color-flow Doppler imaging was used to diagnose neovascularity with the severity of neovessel ingrowth evaluated on a 0–3 ordinal scale, whereby a zero represented no blood vessels visible, 1 indicated mild (one to two vessels extending into tendon), 2 indicated moderate (three to four neovessels), and 3 indicated marked (more than four vessels extending into tendon) neovascularity.

Hypoechoic regions were documented in two ways. The first measured the cross-sectional area of the hypoechoic region in square millimeters using the freehand measurement tool in Intelviewer radiologic software (Version 3.5.1, Intelrad Medical Systems) (Fig. 1). The second evaluation of hypoechoic areas used a 0–3 ordinal scale to document the severity of any given hypoechoic area, whereby a zero represented normal echogenicity and fibular pattern, 1 represented predominately signs of irregular collagen fiber pattern coupled with regions of mild hypoechoic regions, 2 represented larger hypoechoic regions and fiber irregularity, and 3 represented marked hypoechoic regions with periodic anechoic regions. All observable tears were identified as clearly defined anechoic

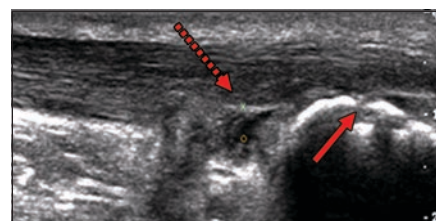
regions within the substance of the tendon proper and were measured in the longitudinal plane in millimeters (Fig. 2). The presence or absence of intratendinous calcification was documented by identifying linear areas of hyperechogenicity within the tendon proper (Fig. 3). Irregularity of the cortical bone of the calcaneus and inflammation of the periosteum were identified as interrupted regions in the bony contour of the cortical bone and small hyperechoic areas emanating at an angle to the cortex, respectively.

### Hyperosmolar Dextrose Injection

A 2.5-mL syringe was filled with 1 mL of 2% lignocaine (20 mg/mL) and 1 mL of 50% dextrose (25g/50 mL) (dextrose monohydrate 500 mg) giving a 25% dextrose solution. Care was taken to expel all the air from the syringe and needle before the injection. The injection procedure was performed under aseptic conditions using a 27-gauge needle (Fig. 4). Abnormal hypoechoic areas and anechoic clefts or foci in the thickened portion of the Achilles tendon were targeted under sonographic guidance using the 7–15 MHz hockey stick linear array transducer (Fig. 5). The volume of solution injected varied slightly from tendon to tendon and depended on the degree of resistance, spread of solution within the tendon, and extent of the abnormality. Generally less than 0.5 mL was injected at any one site. Between 1 and 3 sites were injected during a treatment session. The tendon was reimaged after the injection procedure to assess for spread of the dextrose solution and

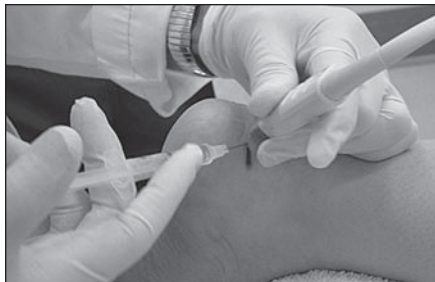

**Fig. 2**—Sonogram in 55-year-old woman with intratendinous tear seen between marks within tendon midsubstance.



**Fig. 3**—Sonogram in 63-year-old man shows irregularity to cortex of calcaneus (solid arrow) and intratendinous calcification (dotted arrow) at Achilles tendon insertion.

## Sonographically Guided Dextrose Injections for Achilles Tendinosis



**Fig. 4**—Photograph of sonographically guided dextrose injection procedure on 60-year-old man with chronic insertional Achilles tendinosis shows simultaneous use of ultrasound probe and 27-gauge needle to target significant sonographic features.

identify any intrasubstance or partial tears that became more conspicuous after the injection.

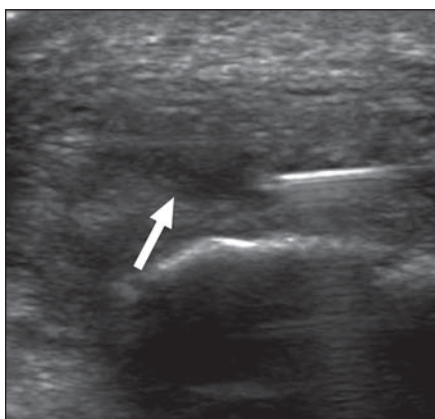
The patient was instructed to refrain from any heavy loading activity during the week after the procedure. Patients were cautioned against taking aspirin or other antiinflammatory agents to relieve any discomfort. Acetaminophen-based analgesia was allowed.

The patient was asked to return for repeat sonography and injection approximately every 6 weeks depending on scheduling. This continued until either the patient's symptoms resolved or no improvement was evident, at which time the treatment was discontinued.

### Data Collection

At the initial consultation, all patients were asked to fill out an information questionnaire containing brief questions regarding their condition, including participation in sporting activity, length of symptomatic period, previous and current treatments, and level of disability.

Visual analog scale (VAS) scores (0–100) were recorded for assessment of pain at the baseline con-



**Fig. 5**—Transverse view of 63-year-old man with chronic insertional Achilles tendinosis shows intratendinous injection procedure with needle targeting hypoechoic region (arrow).

sultation (pretest) and at the final treatment consultation (posttest). VAS scales have been shown to be reliable, valid, and responsive tools in assessing pain levels in patients rehabilitating from a musculoskeletal condition [13]. Patients were asked to complete a visual analog scale item for pain at rest (VAS1), pain during normal daily activity (VAS2), and pain during or after sporting or other physical activity (VAS3). A follow-up telephone interview conducted a mean of 28.6 months (range, 12–48 months) after the patient's final treatment session (follow-up) assessed long-term outcomes by asking the patients to rate their current levels of pain at rest, during activities of daily living, and during or after sports or activity on a scale from zero to 100.

### Data Analysis

Descriptive and mean comparisons of the study data were analyzed using statistical software (version 16.0.0, SPSS). After a test of the homogeneity of variances and one-way analysis of variance determined whether a significant difference in the pain score outcomes was reported for the patients across all three testing times. Post-hoc analysis using Tukey's least significant difference for homogeneous variance or a Dunnett T3 correction if the variance was not homogeneous across groups were applied if there was a significant difference in an outcome measure of pain between the levels for the independent variable of time. Statistical significance for this study was set at a *p* value of 0.05. Trends are suggested at *p* values less than 0.10.

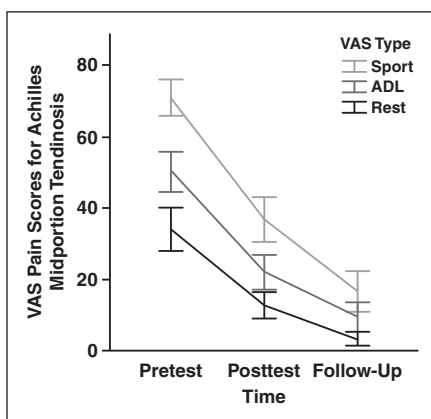
### Results

One hundred eight consecutive tendons from 99 patients (nine patients had bilater-

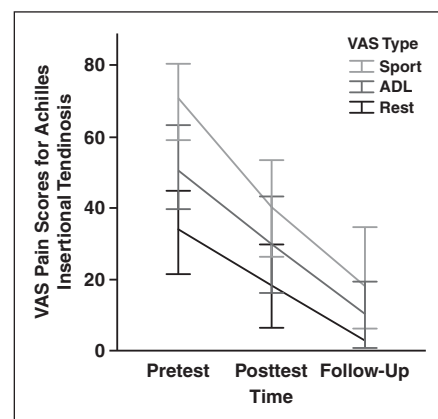
al symptoms) (58 men and 41 women; mean age,  $54.0 \pm 10.8$  years) with chronic Achilles tendinosis with symptoms for a minimum of 6 months (median, 21 months; range 7–228 months) participated in this prospective case series. Eighty-six of the cases were at the Achilles midportion, and 22 had documented pain and pathology at the insertion. A median number of five (range, 1–13) injection consultations were recorded for each patient, spaced an average of  $5.6 \pm 3.1$  (SD) weeks apart. The average time elapsed from pretest to posttest was 28 weeks (range, 5–73 weeks).

Follow-up data were obtained from 71 patients. Two patients (each with unilateral symptoms) informed us at follow-up that they had subsequently gone on to have successful surgery on their Achilles tendon as a result of the dextrose injection protocol being ineffective against their tendon pain, and their data were not included in the follow-up analysis. Consequently, data from the remaining 69 patients (73 tendons (68%) were included in the final follow-up analysis.

Every tendon imaged at baseline had an observable abnormality. There was a significant improvement in the pain scores for both the midportion and insertional groups from baseline to the final consultation (posttest) for all of the pain scores except for VAS1 in the group with insertional Achilles tendinosis (Figs. 6 and 7). The mean differences in all of the pain scores continued to improve as recorded at the mean 28-month follow-up, whereby all pain scores for both Achilles tendon injury sites were significantly lower



**Fig. 6**—Graph shows overview of change from baseline to 28 weeks posttest and subsequent 28-month follow-up for visual analog scale (VAS) item scores for pain at rest, during activities of daily living (ADL), and during or immediately after sports participation (Sport) after individuals received injections of hyperosmolar dextrose for chronic Achilles midportion tendinosis. Bars indicate 95% CI.



**Fig. 7**—Graph shows overview of change from baseline to 28 weeks posttest and subsequent 28-month follow-up for visual analog scale (VAS) item scores for pain at rest, during activities of daily living (ADL), and during or immediately after sports participation (Sport) after individuals received injections of hyperosmolar dextrose for chronic Achilles insertional tendinosis. Bars indicate 95% CI.

at follow-up compared with baseline (Tables 1 and 2).

Improvements in pain corresponded with improvements in some aspects of the sonographic appearance of the Achilles tendon (Fig. 8). A significant reduction in the size of intratendinous tearing was observed for the midportion group, with a trend ( $p < 0.10$ ) for a reduction in the tear size for the insertional patients observed (Table 3). The size of the hypochoic region was reduced only in the patients with midportion tendinosis ( $p < 0.10$ ). There were no differences in the recorded thicknesses of the Achilles tendon at either injury site.

There was a greater reduction in the number of patients with both grade 3 or 2 hypochoic and neovascularization in the midportion group at posttest compared with the insertional group (Tables 4 and 5). The insertional group had more observable cases of intratendinous calcification and cortical irregularities than the midportion group; however, there were no appreciable differences in either of these features from baseline to posttest.

**Discussion**

Achilles tendinosis with pain and degeneration at either the tendon midportion or at the insertion (enthesis) is a common soft-tissue injury predominantly affecting individuals who must bear weight for prolonged periods of time in the day and athletes involved in running-based sports. In severe and chronic cases, it presents a considerable challenge for the health care professional because of limited knowledge of the source of pain and lack of consensus on appropriate management strategies.

The current study reports significant short-term and long-term improvements in the pain scores after patients with Achilles tendinosis at both the insertion and tendon midportion had received sonographically guided injections of dextrose. The positive outcomes from this study confirm the findings from our earlier pilot study on the same patient population and expand those findings with, on average, a follow-up duration that is more than two times longer than previously reported. Both Achilles tendon pathology sites also showed corresponding improvements in the sonographic appearance of the tendon, in particular, a reduction in the size and severity of hypochoic regions, intratendinous tears, and neovascularization. Although there was an improvement in tendon echotexture in the midportion group at post-

**TABLE 1: Summary of Visual Analog Scale Items for Patients Experiencing Midportion Achilles Tendinosis**

Midportion Achilles	Pretest (Mean ± SD)	Posttest (Mean ± SD)	Follow-Up (Mean ± SD)	Mean Change in ES Pretest to Posttest	Mean Change in ES Pretest to Follow-Up
VAS1	34.1 ± 27.7	12.6 ± 16.5	3.3 ± 7.42	21.3 <sup>a</sup> (0.93)	30.8 <sup>a</sup> (1.4)
VAS2	50.2 ± 25.6	21.8 ± 21.8	9.5 ± 16.	28.2 <sup>a</sup> (1.2)	40.7 <sup>a</sup> (1.9)
VAS3	70.7 ± 23.3	36.7 ± 28.0	16.7 ± 22.0	34.0 <sup>a</sup> (1.3)	54.0 <sup>a</sup> (2.4)

Note—ES is a measure of the effect size on the difference represented as Cohen's difference. VAS1 = pain at rest, VAS2 = pain with activities of daily living, VAS3 = pain during or immediately after sports participation. Data in parentheses are effect sizes (Cohen's *d*) for respective differences.  
<sup>a</sup>Indicates a significant difference between time interval to a *p* value of 0.001. ES is a measure of the effect size of the difference represented as Cohen's *d*.

**TABLE 2: Summary of Visual Analog Scale Items for Patients Experiencing Insertional Achilles Tendinosis**

Insertional Achilles	Pretest (Mean ± SD)	Posttest (Mean ± SD)	Follow-up (Mean ± SD)	Mean Change in ES Pretest to Posttest	Mean Change in ES Pretest to Follow-Up
VAS1	33.0 ± 26.5	18.0 ± 25.8	2.7 ± 6.0	14.9 (0.58)	30.2 <sup>c</sup> (1.5)
VAS2	51.3 ± 25.4	29.6 ± 29.4	10.0 ± 16.3	21.7 <sup>a</sup> (0.80)	41.3 <sup>c</sup> (1.6)
VAS3	69.6 ± 24.5	39.8 ± 29.6	17.7 ± 29.1	29.9 <sup>b</sup> (1.1)	51.9 <sup>c</sup> (2.0)

Note—ES is a measure of the effect size on the difference represented as Cohen's difference. VAS1 = pain at rest, VAS2 = pain with activities of daily living, VAS3 = pain during or immediately after sports participation. Data in parentheses are effect sizes (Cohen's *d*) for respective differences.  
<sup>a</sup>Indicates a significant difference between time interval to a *p* value of 0.05.  
<sup>b</sup>Indicates a significant difference between time interval to a *p* value of 0.01.  
<sup>c</sup>Indicates a significant difference between time interval to a *p* value of 0.001.

test, the size of the hypochoic regions and the overall severity of the hypochoic regions remained relatively unchanged in the insertional group. In addition, the insertional group registered more patients with calcific changes within the tendon and irregularities of the cortical bone of the calcaneus.

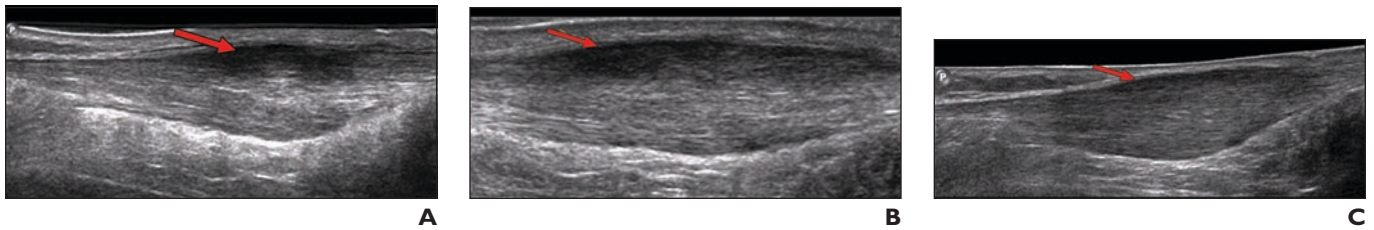The patient group in this study represented a population with chronic long-standing symptoms (median, 21 months of symptom duration; range, 7–228 months) who had already sought treatment from their primary care physician or sports medicine specialist and were then further referred for the sonographically guided dextrose injection treatment. Because of the resources involved in carrying out the dextrose injections (i.e., ultrasound machine and radiologist trained in musculoskeletal pathology) and the needle-stick injury involved, it is suggested that this treatment be administered only after conservative measures have been deemed ineffective.

For patients in whom conservative treatment measures for tendinosis, such as ice, rest, activity modification, footwear changes, and shoe orthoses have failed, there are other more aggressive or experimental treatment options reported in the literature. These include heavy-load eccentric-only heel drops;

extracorporeal shockwave therapy; or injections of autologous blood, sclerosing agents (polidocanol), platelet-rich plasma (PRP) preparations, or stem cells [14–19]. Some of these treatment options, such as a heavy-load heel-drop program may not be appropriate or may pose challenges in patient compliance for certain populations. Other options, at least in Canada, are coupled with a significant financial cost (extracorporeal shockwave therapy) or include agents that are not readily available (polidocanol injections). Autologous blood or PRP injections require additional steps of blood withdrawal (and centrifugation with PRP and hematopoietic stem cells) before readministering the treatment injection. Injection of bone marrow stromal stem cells is still too invasive and experimental in nature to be considered a viable treatment option.

Injections of dextrose have been used individually for a variety of musculoskeletal indications: lower back pain and sacroiliac joint dysfunction [20], knee instability subsequent to anterior cruciate ligament injury [21], osteoarthritis [22], anterior talofibular ligament sprain, and medial meniscus injury [23]. Specifically in the context of tendinopathy, dextrose prolotherapy has shown clinical efficacy according to case

## Sonographically Guided Dextrose Injections for Achilles Tendinosis



**Fig. 8**—Improvement in echotexture seen in 55-year-old woman with chronic midportion Achilles tendinosis.

**A**, Sonogram shows grade 3 hypoechogenicity in superior midsubstance of tendon (*arrow*).

**B**, Sonogram shows mild improvement in echotexture (*arrow*) (now grade 2) 14 weeks after starting dextrose injection therapy.

**C**, Sonogram obtained 52 weeks after treatment onset shows continued improvement in echotexture (*arrow*) in addition to collagen organization with only mild degree of hypoechogenicity (now grade 1). Note lack of change in tendon thickness throughout.

**TABLE 3: Overview of Continuous Sonographic Variables Across Time Subdivided for Patients With Pain at Either the Achilles Midportion or Insertion**

Sonographic Feature	Test Time	
	Pretest	Posttest
<b>Midportion</b>		
Tendon thickness (mm ± SD)	10.1 ± 2.9	10.4 ± 2.4
Size of hypoechoic region (mm <sup>2</sup> ± SD)	81.60 ± 108.7	52.1 ± 87.1 <sup>a</sup>
Intratendinous tear size (mm ± SD)	7.1 ± 6.4	3.1 ± 4.7 <sup>b</sup>
<b>Insertion</b>		
Tendon thickness (mm ± SD)	10.5 ± 3.4	10.1 ± 2.6
Size of hypoechoic region (mm <sup>2</sup> ± SD)	178.6 ± 119.8	176.5 ± 112.6
Intratendinous tear size (mm ± SD)	5.3 ± 4.5	1.6 ± 2.8 <sup>a</sup>

<sup>a</sup>Indicates a significant difference between time interval to a *p* value of 0.01.

<sup>b</sup>Indicates a significant difference between time interval to a *p* value of 0.10.

**TABLE 4: Overview of Ordinal or Dichotomous Sonographic Variables Across Time Subdivided for Patients With Pain at the Achilles Midportion**

Sonographic Feature (Midportion)	Test Time	
	Pretest	Posttest
<b>Echotexture severity</b>		
Grade 0	35	50
Grade 1	13	21
Grade 2	31	14
Grade 3	7	1
<b>Degree of neovascularity</b>		
Grade 0	22	38
Grade 1	20	28
Grade 2	36	20
Grade 3	8	0
Intratendinous calcification	1	1
Cortical irregularity	2	2
Periostitis	0	0

series data at the following locations: adductor tendinopathy in elite soccer and rugby athletes [24], patellar tendinopathy [23], and Achilles insertional and noninsertional tendinopathy [11].

Dextrose, similar to other prolotherapy-based agents, is understood to elicit a proliferant cellular response by inducing inflammation, subsequent growth factor production

leading to increased fibroblast proliferation (either locally or systemic), and increased production of extracellular matrix materials [25]. Dextrose is considered primarily an osmotic agent creating cellular dysfunction and loss of membrane integrity via increases in osmotic pressure from the introduction of the hypertonic solution [26].

Mechanistic background research on the effects of isolated dextrose prolotherapy is not extensive and reports are inconclusive. Jensen et al. [27] compared three different prolotherapy solutions (dextrose; lidocaine, dextrose, and glycerin solution [Proliferol, CAM Research Institute]; and sodium morrhuate) on the effect of knee ligaments in a healthy rat model. The response from all of the prolotherapy solutions was varied and, overall, not significantly different from that of the needle-stick injury or saline injection control subjects. Injections of dextrose prolotherapy, this time in a rat injury model, have resulted in an increase in the cross-sectional area of medial collateral ligament tissue compared with saline-injected controls [28].

Improvements in the amount and severity of hypoechoic areas (in addition to a reduction in tear size) in the midportion group of the current study are likely a result of positive tissue remodelling subsequent to a proinflammatory response after the injection. After appropriate introduction of local and transitory growth factors (via platelets) for tissue repair, increased fibroblast production and maturation of collagen type 1 would result [8]. Over time, the newly laid foundation of collagen becomes oriented in the direction of tensile strain, resulting in its characteristic organized and wavy sonographic or histologic appearance [29]. Presumably, this process of collagen type 1 deposition and maturation would alter the acoustic properties of that portion of the tendon, giving an appearance of increased echogenicity and a more normal fibrillar pattern. Although the precise cause

**TABLE 5: Overview of Ordinal or Dichotomous Sonographic Variables Across Time Subdivided for Patients With Pain at the Achilles Insertion**

Sonographic Feature (Insertion)	Test Time	
	Pretest	Posttest
Echotexture severity		
Grade 0	2	3
Grade 1	3	10
Grade 2	12	9
Grade 3	5	5
Degree of neovascularity		
Grade 0	1	10
Grade 1	6	5
Grade 2	12	7
Grade 3	3	0
Intratendinous calcification	11	10
Cortical irregularity	5	6
Periostitis	1	2

for persistent blood vessel infiltration during tendinosis is unclear, the decrease in neovascularity observed in the current study corresponding with an improved clinical outcome may reflect an advanced state of healing whereby the blood vessel (and associated nerve fibers) have retreated from the tendon proper [30]. Because the injection protocol was similar at both the Achilles insertion and midportion, we are curious why a similar effect of the echotexture of the tendon was not observed in the insertional group.

The median number of injections used in this study to achieve a satisfactory clinical outcome (as determined by the patient) was five. The range of injections documented in the current study presumably reflects a variance in the responsiveness of tissues to the injection stimuli and the patient's willingness to return for a further injection. There did not appear to be any correlation between the number of injections and the clinical efficacy of the procedure; therefore, at this point there does not appear to be an optimum number of injections to incite therapeutic response in the Achilles tendon.

A similar treatment protocol by Alfredson and Öhberg [18] involving injections of a sclerosing agent, polidocanol, into the peritendinous space ventral to the Achilles tendon reported successful pain and satisfaction outcomes for patients experiencing either midportion or insertional Achilles tendinosis. The primary difference between the procedure described in the current study versus that of Alfredson and Öhberg is a change in

the injection target from infiltrating blood vessels to intratendinous structural defects, such as tears or hypoechoic regions. In contrast to their findings, the current study reported the presence of neovascularization remaining at either a mild to moderate level in 60 cases at the posttest stage, suggesting an alternate, or complimentary, source of pain apart from that suggested by Alfredson et al. [31] for this patient group. The results from the current study appear in agreement with Zanetti et al. [32] who reported similar trends in their association with tendon echotexture, presence of neovessels, and pain.

The recent reported use of percutaneous tenotomy (tendon fenestration) administered under sonographic guidance opens the question of the necessity of using an alleged hyperosmotic agent (dextrose), or any injectable therapeutic agent for that matter, to achieve a clinically meaningful reduction in pain. Reported outcomes from case series data after patients who had tendinosis at the common elbow extensor and received a percutaneous tenotomy procedure appear promising, with good patient satisfaction and return to activity scores [33, 34]. A smaller case series with four patients who had Achilles tendinosis also reported favorable outcomes after percutaneous tenotomy treatment [35]. More research is needed to confirm the clinical effectiveness of the use of percutaneous tenotomy for chronic tendinosis, and a direct comparison incorporating both tenotomy and dextrose treatment arms would offer important insights on standardized treatment

effects in the area of interventional radiology for chronic tendinosis.

The current study's strength of evidence for the treatment effects of the sonographically guided dextrose injections is compromised in that there is no control group included and no randomization protocol. The available data from the sonographic changes reported would also be improved with the addition of sonographic evaluation of the patients at the 28-month follow-up point. Such a sonographic evaluation would help to provide an insight onto the improvements in pain reported in both Achilles tendon pathology groups at follow-up over their posttest values. In other words, would we continue to see improvements in the sonographic appearance of the tendons 28 months after the test, and would these changes be correlated with the improvements in pain?

In conclusion, the current study expands on the positive outcomes reported previously by our group for the use of sonographically guided dextrose injections for midportion and insertional Achilles tendinosis by including results from now 108 tendons in 99 patients with an average follow-up duration of more than 2 years. Future research is under way to conduct a clinical trial including injection and noninjection control groups to strengthen the evidence for this promising treatment alternative.

## References

1. Clement DB, Taunton JE, Smart GW. Achilles tendinitis and peritendinitis: etiology and treatment. *Am J Sports Med* 1984; 12:179–184
2. Kujala UM, Sama S, Kaprio J. Cumulative incidence of Achilles tendon rupture and tendinopathy in male former elite athletes. *Clin J Sport Med* 2005; 15:133–135
3. Taunton JE, Ryan M, Clement DB, McKenzie D, Lloyd-Smith D, Zumbo B. A retrospective case-control analysis of 2002 running injuries. *Br J Sport Med* 2002; 36:95–101
4. Paavola M, Kannus P, Järvinen T, Khan K, Jozsa L, Järvinen M. Current concepts review: Achilles tendinopathy. *J Bone Jt Surg* 2002; 84A:2062–2076
5. Cook JL, Khan KM, Purdam C. Achilles tendinopathy. *Man Ther* 2002; 7:121–130
6. Alfredson H, Lorentzon R. Chronic Achilles tendinosis: recommendations for treatment and prevention. *Sports Med* 2000; 29:135–146
7. Nakama L, King K, Abrahamsson S, Rempel D. Evidence of tendon microtears due to cyclical loading in an in vivo tendinopathy model. *J Orthop Res* 2005; 23:1199–1205
8. Kjær M. Role of extracellular matrix in adaptation

## Sonographically Guided Dextrose Injections for Achilles Tendinosis

- of tendon and skeletal muscle to mechanical loading. *Physiol Rev* 2004; 84:649–698
9. Maffulli N, Regine R, Angelillo M, Capasso G, Filice S. Ultrasound diagnosis of Achilles tendon pathology in runners. *Br J Sports Med* 1987; 21: 158–162
  10. Leung J, Griffith J. Sonography of chronic Achilles tendinopathy: a case-control study. *J Clin Ultrasound* 2008; 36:27–32
  11. Maxwell NJ, Ryan MB, Taunton JE, Gillies GH, Wong AD. Sonographically guided intratendinous injection of hyperosmolar dextrose to treat chronic tendinosis of the Achilles tendon: a pilot study. *AJR* 2007; 189:947; [web]W215–W220
  12. Ryan MB, Wong AD, Gillies GH, Wong J, Taunton JE. Sonographically guided intratendinous injections of hyperosmolar dextrose/lidocaine: a pilot study for the treatment of chronic plantar fasciitis. *Br J Sports Med* 2009; 43:303–306
  13. Boonstra A, Schiphorst Preuper H, Reneman M, Posthumus J, Stewart R. Reliability and validity of the visual analogue scale for disability in patients with chronic musculoskeletal pain. *Int J Rehabil Res* 2008; 31:165–169
  14. Scarpone M, Rabago D, Zgierska A, Arbogest J, Snell E. The efficacy of prolotherapy for lateral epicondylitis: a pilot study. *Clin J Sport Med* 2008; 18:248–254
  15. Alfredson H, Pietilä T, Jonsson P, Lorentzon R. Heavy-load eccentric calf muscle training for the treatment of chronic Achilles tendinosis. *Am J Sports Med* 1998; 26:360–366
  16. Costa M, Shepstone L, Donell S, Thomas T. Shock wave therapy for chronic Achilles tendon pain: a randomized placebo-controlled trial. *Clin Orthop Relat Res* 2005; 440:199–204
  17. Connell D, Ali K, Ahmad M, Lambert S, Corbett S, Curtis M. Ultrasound-guided autologous blood injection for tennis elbow. *Skeletal Radiol* 2006; 35:371–377
  18. Alfredson H, Öhberg L. Sclerosing injections to areas of neo-vascularisation reduce pain in chronic Achilles tendinopathy: a double-blind randomised controlled trial. *Knee Surg Sports Traumatol Arthrosc* 2005; 13:338–344
  19. Smith RK. Mesenchymal stem cell therapy for equine tendinopathy. *Disabil Rehabil* 2008; 30: 1752–1758
  20. Yelland M, Glasziou P, Bogduk N, Schluter P, McKernon M. Prolotherapy injections, saline injections, and exercises for chronic low-back pain: a randomized trial. *Spine* 2004; 29:9–16
  21. Reeves KD, Hassanein K. Long term effects of dextrose prolotherapy for anterior cruciate ligament laxity. *Alternative Ther Health Med* 2003; 9:58–62
  22. Reeves KD, Hassanein K. Randomized, prospective, placebo-controlled double-blind study of dextrose prolotherapy for osteoarthritic thumb and finger (DIP, PIP, and trapeziometacarpal) joints: evidence of clinical efficacy. *J Altern Complement Med* 2000; 6:311–320
  23. Fullerton B. High-resolution ultrasound and magnetic resonance imaging to document tissue repair after prolotherapy: a report of 3 cases. *Arch Phys Med Rehabil* 2008; 89:377–385
  24. Topol G, Reeves D, Hassanein K. Efficacy of dextrose prolotherapy in elite male kicking-sport athletes with chronic groin pain. *Arch Phys Med Rehabil* 2005; 86:697–702
  25. Cusi M, Saunders J, Hungerford B, Wisbey-Roth T, Lucas P, Wilson S. The use of prolotherapy in the sacro-iliac joint. *Br J Sports Med* 2008
  26. Dagenais S, Yelland M, DelMar C, Schoene M. Prolotherapy injections for chronic low-back pain. *Cochrane Database Syst Rev* 2007; 18: CD004059
  27. Jensen K, Rabago D, Best T, Patterson J, Vanderby R. Early inflammatory response of knee ligaments to prolotherapy in a rat model. *J Orthop Res* 2008; 26:816–823
  28. Jensen K, Rabago D, Best T, Patterson J, Vanderby R. Response of knee ligaments to prolotherapy in a rat injury model. *Am J Sports Med* 2008; 36: 1347–1357
  29. Khan KM, Bonar S, Desmond P. et al. Patellar tendinosis (jumper's knee): findings at histopathologic examination, US, and MR imaging. *Radiology* 1996; 200:821–827
  30. Bring D, Kreicbergs A, Renström P, Ackermann P. Physical activity modulates nerve plasticity and stimulates repair after Achilles tendon rupture. *J Orthop Res* 2007; 25:164–172
  31. Alfredson H, Öhberg L, Forsgren S. Is vasculoneural ingrowth the cause of pain in chronic Achilles tendinosis? An investigation using ultrasonography and colour Doppler, immunohistochemistry, and diagnostic injections. *Knee Surg Sports Traumatol Arthrosc* 2003; 11:334–338
  32. Zanetti M, Metzendorf A, Kundert H, et al. Achilles tendons: clinical relevance of neovascularization diagnosed with power Doppler US. *Radiology* 2003; 227:556–560
  33. McShane J, Shah V, Nazarian L. Sonographically guided percutaneous needle tenotomy for treatment of common extensor tendinosis in the elbow: is a corticosteroid necessary? *J Ultrasound Med* 2008; 27:1137–1144
  34. Zhu J, Hu B, Xing C, Li J. Ultrasound-guided, minimally invasive, percutaneous needle puncture treatments for tennis elbow. *Adv Ther* 2008; 25:1031–1036
  35. Housner J, Jacobson J, Misko R. Sonographically guided percutaneous needle tenotomy for the treatment of chronic tendinosis. *J Ultrasound Med* 2009; 28:1187–1192

### FOR YOUR INFORMATION

The comprehensive book based on the ARRS 2009 annual meeting categorical course on *Ultrasound: Practical Sonography for the Radiologist* is now available! For more information or to purchase a copy, see [www.arrs.org](http://www.arrs.org).