



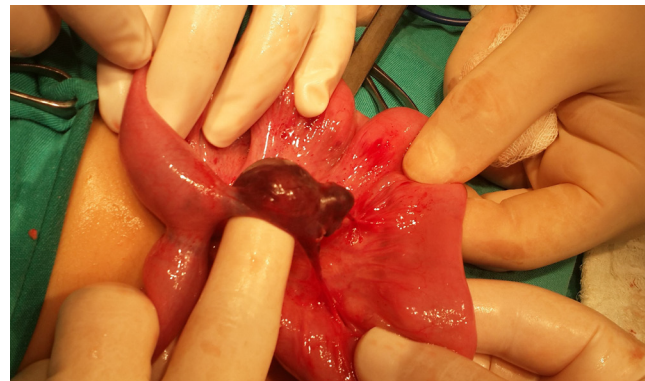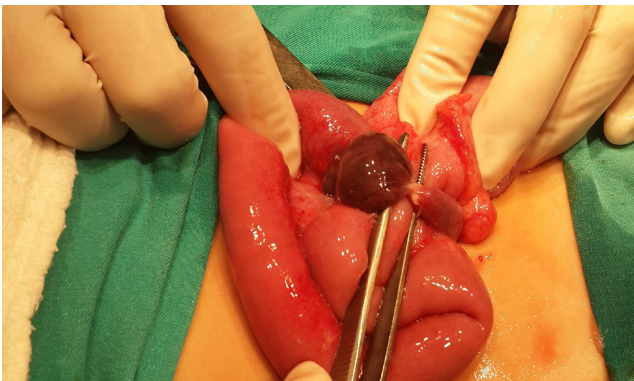
Journal of

Clinical and Analytical Medicine

Vol: 7 No: 5 September 2016

Gangrene of Meckel's Diverticulum Secondary to Axial Torsion in a Child: An Unusual Complication

Suzen A, Erturk N, Topal Y



Contents;

- Demographic Characteristics of 796 Patients Operated for Lumbar Disc Herniation in Thrace Region, Turkey
- Early Childhood Caries with the Perspective of Pediatrician
- Cytogenetic Analysis of 65 Women with Premature Ovarian Insufficiency
- The Evaluation of Uncertainty for the Measurement of Blood Ethanol
- What is the Optimal Treatment of Atrophic Scaphoid Non-Union?
- Views of Turkish Men Regarding the use of Drugs and Products for Increasing Sexual Performance
- Evaluation of Children with Recurrent Fever
- Diagnostic Utility of Ischemic Modified Albumin in Young Adult Patients with Acute Coronary Syndrome
- Evaluation of 61 Secondary Amyloidosis Patients: A Single-Center Experience from Turkey
- Lumbar Spinal Stenosis Due to Ligamentum Flavum Hypertrophy in a Patient with Multiple Exostosis
- A Rare Cause of Dyspnea in Pregnancy: Diaphragmatic Eventration
- Ipsilateral Rotational Autokeratoplasty