

Journal of

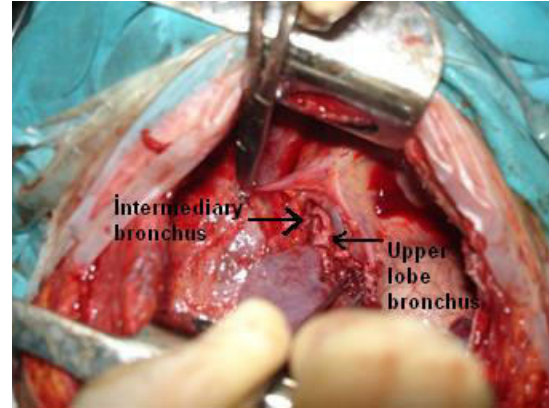
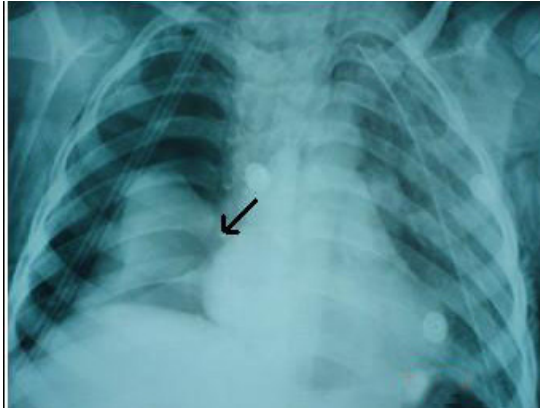Clinical and Analytical Medicine

Klinik ve Analitik Tıp Dergisi

Cilt / Vol: 6 Sayı / No: 3 Mayıs / May 2015

Complete Right Main Bronchus Rupture in a Child: Report of a Case

A. Bayram, C. Sami, S.G. Sadi, C. Ozkan



Contents;

- Six Minute Walk Distance in Stable Chronic Obstructive Pulmonary Disease
- Evaluation of the use of Environmental Asbestos in Siverek
- Is Helicobacter Pylori a Possible Etiopathogenic Factor in Chronic Tonsillitis?
- Our Prostate Biopsy Results in The Patients with Prostate Specific Antigen Levels Below 4 ng/ml
- The Evaluation of the Relationship Between Parvovirus B19 and Hashimoto Thyroiditis
- A Rare Suicidal Method: Succinylcholine Chloride Injection
- A Novel Neonatal Michelin Tire Baby Syndrome with Craniosynostosis and Gigantism
- A Case of Spontaneously Resolved Bilateral Primary Spontaneous Pneumothorax
- Cholecystoenteric Fistule and Laparoscopic Repair
- A Case of Bone Aspiration Mimicking Asthma in an Adult Patient
- The Current Definitions of Health-Care Associated Infections in Intensive Care Units
- Bilateral Globus Pallidus Ischemia: Carbon Monoxide Poisoning