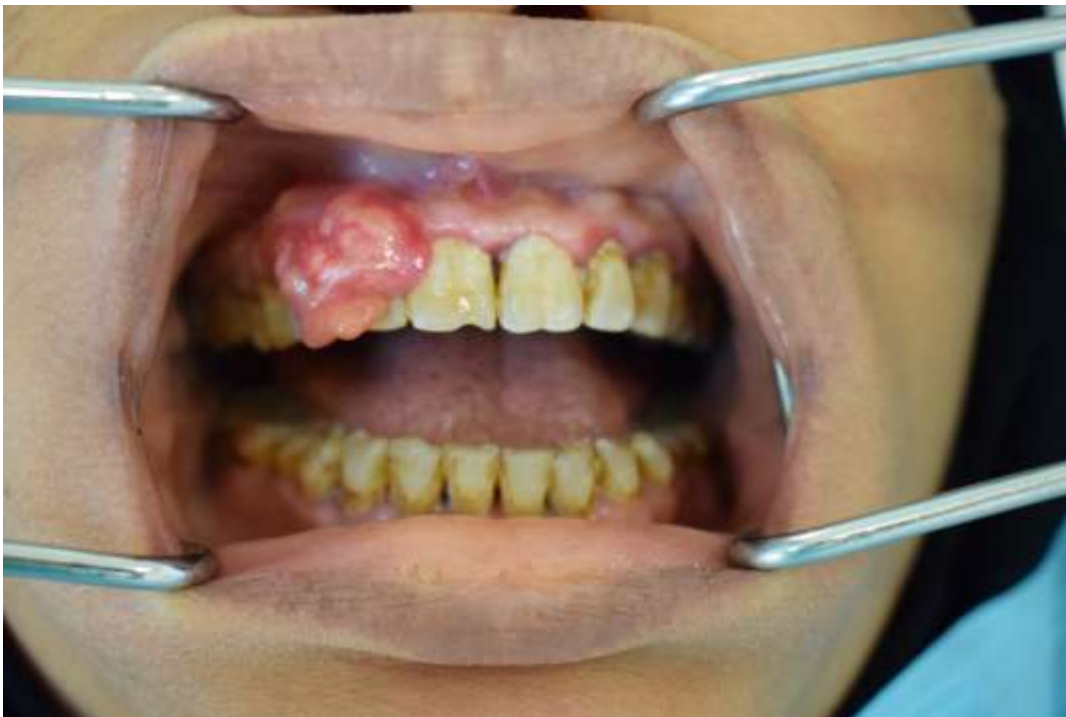

Case 1

The patient was a 50 year old woman with Type II diabetes (on metformin). She presented with an asymptomatic maxillary buccal gingival lesion that was reportedly present for 10 months. The patient had a 40 year history of smokeless tobacco (*shamma*), but no alcohol use.



NOTES:

.....

.....

.....

.....

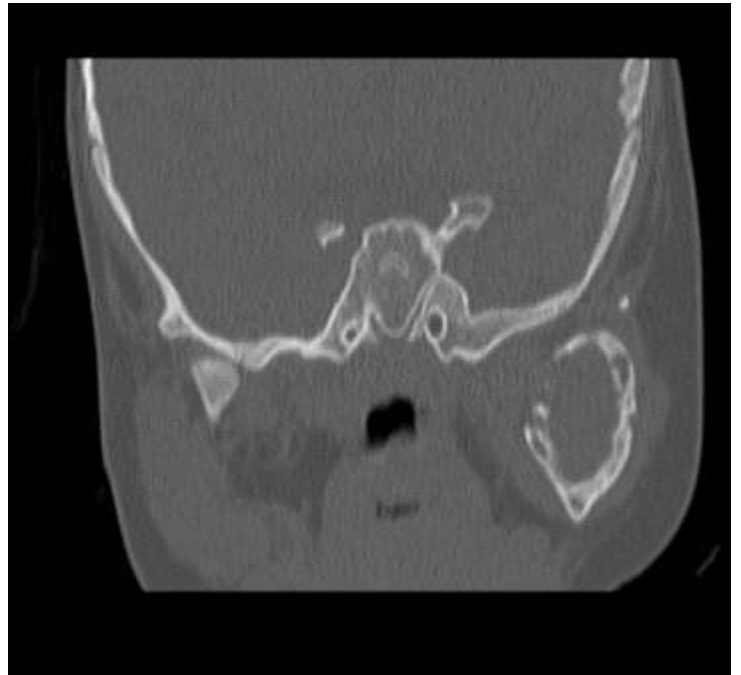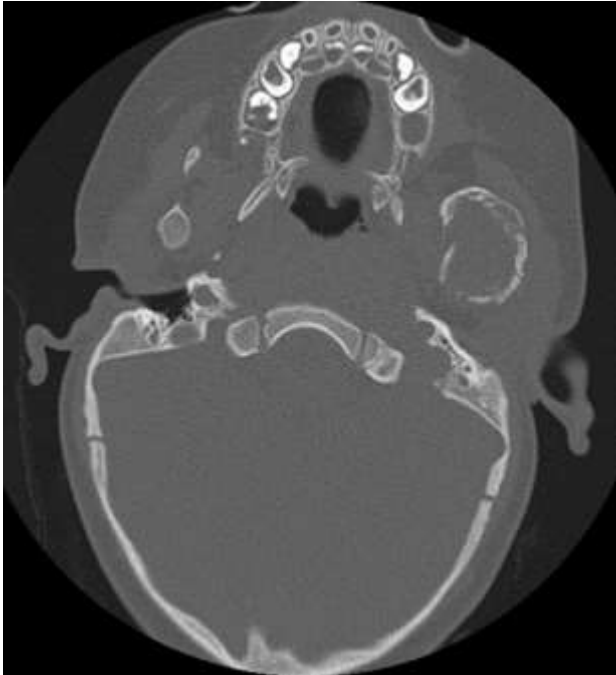
.....

.....

.....

Case 5

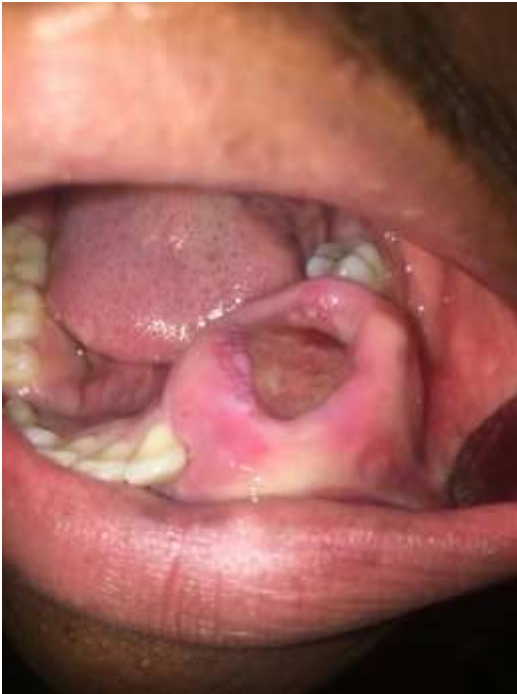The patient was a 1 year old female who presented with asymptomatic left facial swelling. She had been treated previously with two courses of antibiotics without a decrease in the swelling.



NOTES:

Case 6

A 21-year-old male patient presented with a large, ulcerated, and expansile lesion of the left mandible, with loosening of the associated teeth. His past medical history included epilepsy and right leg amputation for “cancer of the knee”. The patient also reported that his grandmother and aunt also had similar jaw swellings.



NOTES:

