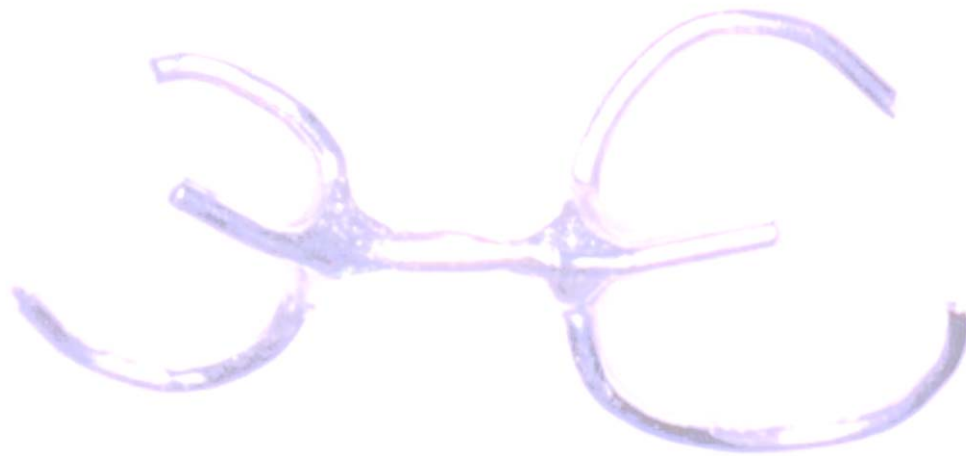

A New Appliance for Forced Eruption

Monira Uddin, D.D.S.; Natia Mosheshvili, D.D.S.; Stuart L. Segelnick, D.D.S., M.S.

Abstract

The purpose of these case reports is to introduce an innovative orthodontic appliance to effect forced eruption. This device is useful when attempting to erupt teeth in the esthetic zone with minimal effect on adjacent teeth. It is especially indicated for adjacent teeth with esthetic restorations. The appliance is easy to fabricate, cost-effective and very useful in forced eruption efforts for the “non-restorable” tooth.

IN OUR DENTAL PRACTICES we are often faced with circumstances that make restorations difficult, if not impossible, because of lack of tooth structure. A common scenario would be one where the tooth has been fractured to the level of the osseous crest.¹ At times, traditional periodontal surgery (crown lengthening) cannot be performed on the tooth in question because of possible compromise of esthetics, osseous support, compromise to adjacent teeth and long-term prognosis to justify treatment.² However, often times, patients do not want to extract their teeth, forcing the practitioner to devise alternative treatment plans. The innovative dentist, mindful of his or her patients’ needs, must then tailor his or her treatment plan to the highest ethical standard.

Forced eruption (orthodontic extrusion) can be used to treat these hopeless teeth, such as those that have destruction of clinical crowns, lateral root perforation and isolated vertical periodontal defects.³ Teeth that have lost part or all of their clinical crowns are

seen daily. Extensive caries, root resorption, fractures, erosion, abrasion, occlusal wear, noxious habits and even iatrogenic origins might be etiologic factors in such loss of tooth structure. Forced eruption is desirable in these cases because of the necessity of restoring these teeth and maintaining the biologic width.

Forced eruption is the best treatment choice in the esthetic zone, as long as the following conditions are maintained:

1. All acute inflammatory periodontal processes are under control.⁴
2. Enough root length will be left within the bone, leaving a minimum 1:1 crown root ratio.
3. Root canal treatment must be completed with the resolution of periapical pathology. Adequate tooth structure for crown or post placement should be maintained to prevent root fracture after the tooth is restored and in function.
4. The tooth has strategic relevance.
5. The overall long-term prognosis of the tooth is good.
6. The patient is motivated and understands it will take several visits.⁵

When working in the esthetic zone, forced eruption can be very challenging. In the past, orthodontic brackets, bonded fixed bars and removable appliances that incorporate tissue support have all been used. Unfortunately, when the adjacent teeth have crowns or veneers, these methods may have deleterious consequences. Porcelain and bonding can chip or fracture leaving the practitioner with no other choice but to restore the adjacent teeth. This in itself may lead to a more esthetic restoration, but was it necessary? And will the patient be happier with the extra cost and treatment time?

Two cases will be presented to introduce the dental community to a device that can be used easily and cost-effectively in these situations for forced eruption. This appliance, which the authors

call the “Forced Erupter,” will be described in detail. The original device was created to forcibly extrude a tooth with no change to the adjacent teeth. The newer appliance also maintains this ideal; however, because of medical/legal considerations, the appliance has undergone changes.

Case One

A 71-year-old man was referred to one of the authors for crown lengthening on tooth #6. The tooth had a previous crown that had recurrent decay. After the caries were removed, the interproximal tooth structure was about level to the osseous ridge (Figure 1). This was confirmed both clinically and radiographically. The patient was missing the following teeth: #1, #2, #3, #4, #15 and #16. Tooth #5 was a crown, and teeth #7 through #14 were part of a fixed bridge.

The option to extract #6 and place an implant or removable partial denture was discussed, but rejected by the patient. To avoid a new fixed bridge and save an existing tooth, the patient chose to have forced eruption. However, with crowns on adjacent teeth and the present methods of forced eruption having an increased risk of porcelain damage, a new appliance was fabricated. It consisted of a bar connecting two C-clasps and two rests (Figure 2). A post was then prepared with duralay and .036 retainer wire (size of a paper clip) and cemented into the canal with duralon, 4 mm below the appliance. The 4 mm depth was used to satisfy the biologic width and crown margin that would be needed for optimal health after the tooth was erupted and restored.

The occlusion was adjusted (Figure 3) and a fibrotomy was accomplished. Then the Forced Erupter was activated with 0.03 elastomeric tubing. The tubing was changed weekly and reactivated, at which time a fibrotomy was also performed. This lasted for six weeks when the post was in contact with the bar portion of the Forced Erupter.

During the first two weeks, only .5 mm of eruption occurred, which may be attributed to the author’s first time activating the appliance. After that, there was nearly 1 mm of eruption per week (Figure 4).

At the end of the sixth week, crown lengthening was done to correct the gingival contours. At the same time, an assessment was made to see if the root had erupted without bringing down the osseous support. The surgery confirmed that the bone did not erupt with the tooth, and no bone was removed (Figure 5). A radiograph was also taken that showed that the tooth had erupted and 4 mm radiolucency at the apex could be seen (Figure 6). This radiolucency filled with bone by the eighth week and could not be seen on X-rays any longer. The post was then removed and a temporary crown placed.

After six weeks of stabilization, a new crown was fabricated. A photo was taken two and one-half years later to show how the restorations and gingival support on #6 was maintained (Figure 7). The patient still has the tooth and is quite happy five years later.

Case Two

A 40-year-old woman presented to the dental clinic at New York Hospital Queens at the end of December 2003. There was very little remaining tooth structure on tooth #13 and a crown-lengthening

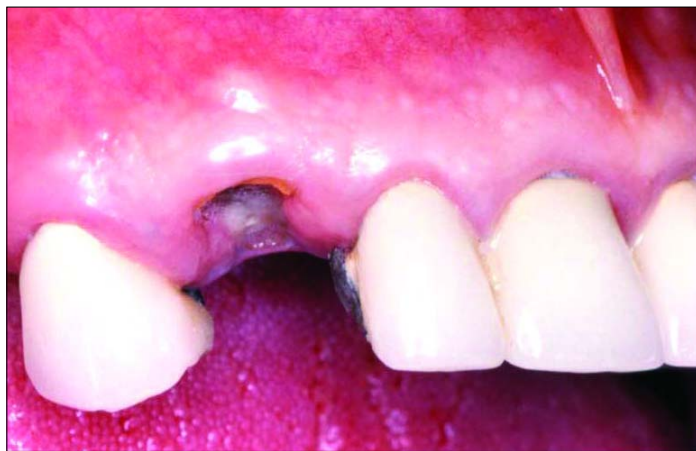

Figure 1. Initial presentation of tooth #6 below gingiva.

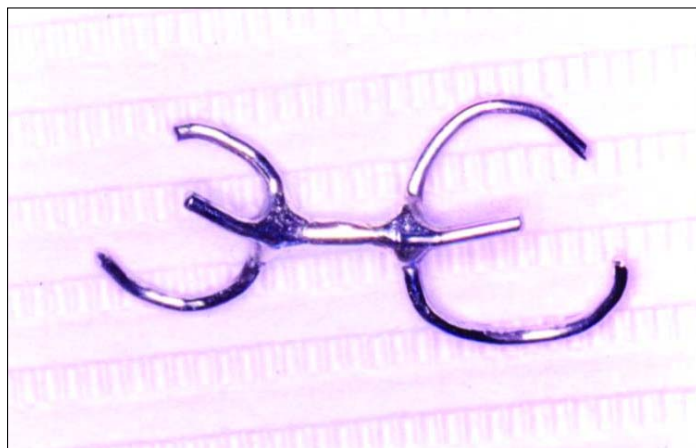


Figure 2. Device for forced eruption.

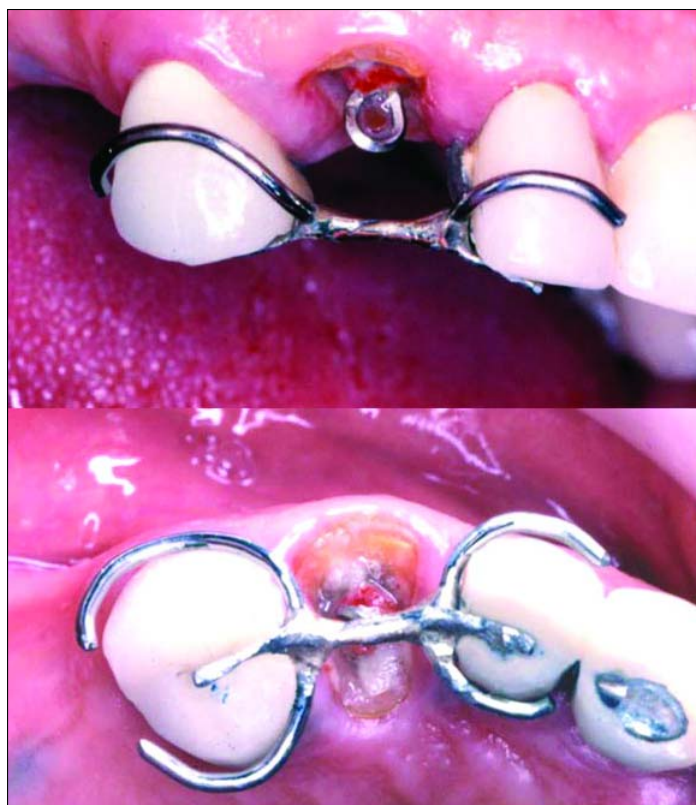

Figure 3. Appliance placed 4 mm below post hook and then centered with occlusal adjustment.

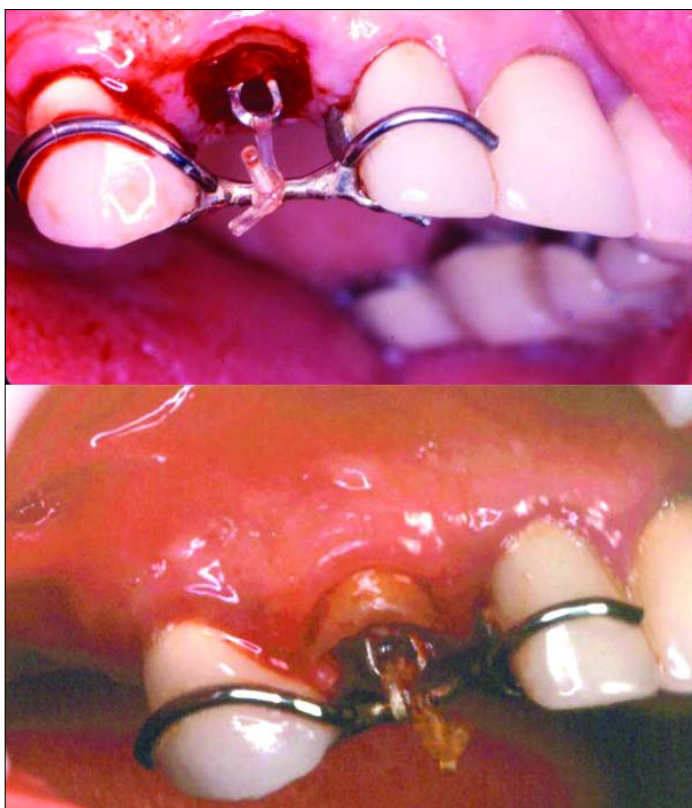


Figure 4. Elastomeric tubing activated and tooth eruption completed. Note post now flush with Forced Erupter's bar.

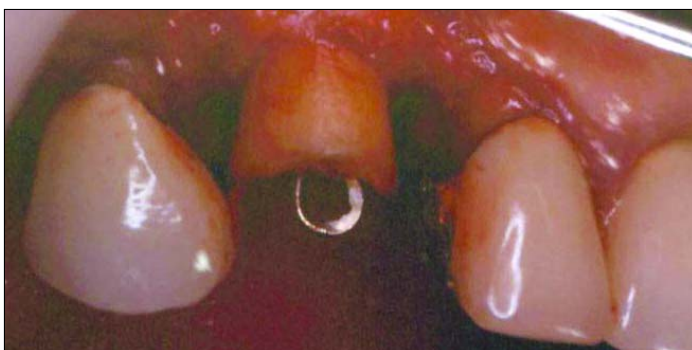

Figure 5. Tooth erupted without bringing down attachment (bone).

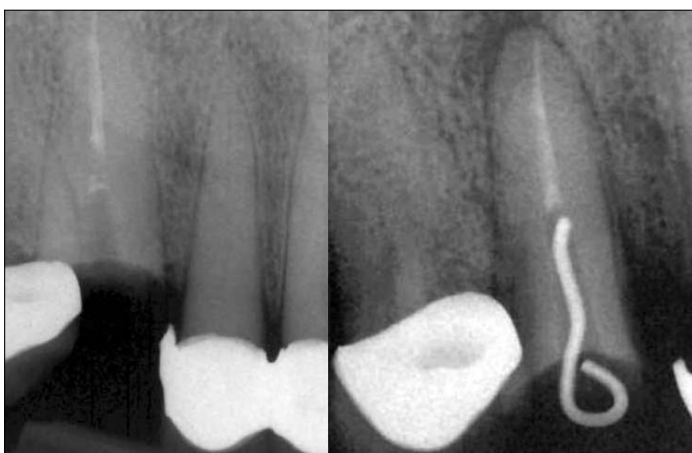

Figure 6. Radiographs depicting before and after. Note 4 mm of apical radiolucency immediately after eruption.

procedure was recommended (Figure 8). However, after careful review, it was decided that too much bone would have to be compromised from the adjacent teeth for crown lengthening to be advantageous. So, forced eruption with the Forced Erupter was suggested.

From the time the first case study was completed, the Forced Erupter had evolved (Figure 9). A cast post was fabricated and a horizontal hole was placed in the post wide enough to thread the elastomeric tubing. The post was cemented and a 3 mm space between the post and the bar of the Forced Erupter was achieved. The device was bonded onto the adjacent teeth with composite and an occlusal adjustment was also completed (Figure 10). Elastomeric tubing (0.30) was activated and a fibrotomy was accomplished under local anesthetic. The patient then returned weekly for three weeks, at which time the tubing was replaced and fibrotomies were performed.

The tooth erupted about 1 mm per week until the post was in close proximity with the bar of the appliance (Figure 11). This confirmed 3 mm of tooth eruption. The tooth was temporized and subsequently retained for eight weeks. The patient did not return for the permanent crown because of scheduling conflicts and as of this date, we are still trying to accommodate her.

Discussion

It is important that biologic width is not encroached upon when restoring teeth. Doing so can lead to a host of periodontal problems and to the ultimate failure of the final restoration. The biologic width, a concept first described by Garguilo and Associates,^{6,7} is a combination of the connective-tissue attachment and the junctional epithelium.

In a healthy adult, this width usually measures an average of 2.04 mm. The average distance, as studied on cadavers, from the alveolar bone crest to the cemento-enamel junction is 1.07 mm. The width of the epithelial attachment coronal to the connective tissue attachment is 0.97 mm. To place a restorative margin with adequate marginal seal, one needs an additional 1 mm to 2 mm of sound tooth structure, thus making the total minimum amount of tooth structure needed for a sound restoration to be between 3 mm and 4 mm to prevent any violation of the biologic width. In cases where the gingiva is thicker and flatter, 4 mm of total tooth structure from the alveolar crest is necessary.⁸

Heithersay and Ingber were the first to suggest the use of forced eruption to treat "non-restorable" or previously "hopeless" teeth.⁹ Since then, different clinicians have used various techniques to extrude teeth using removable devices^{10,11} or fixed brackets.¹² The ultimate goal of all of these techniques has been to expose sound tooth structure, maintain an acceptable crown-to-root ratio, and to establish a biologic width before restoring the tooth, all the while maintaining good periodontal health.¹¹

Forced eruption should be considered in cases where traditional crown lengthening via ostectomy cannot be accomplished. In the anterior area, it is difficult to do an ostectomy without an esthetic deformity. Ostectomy also removes bone from adjacent teeth, which can compromise the function of these teeth. It can also compromise a tooth that already had questionable support or lead to an inverse

root-to-crown ratio with an increased clinical crown.¹³ Some of the contraindications to forced eruption are inadequate crown-to-root ratio, lack of occlusal clearance for the required amount of eruption and any possible periodontal complications. Forced eruption is generally best in the anterior region where esthetics is important and ostectomy can lead to negative architecture.¹⁴

Forced eruption is a viable option open to most dentists. Some colleagues have published their findings while others have relied on anecdotal reports to get their methods across to their colleagues. The majority of these studies have found that the tooth's attachment apparatus also moves along with the tooth. Based on these reports, the general rule is to allow about one to one and one-half weeks for each mm of extrusion.¹⁴ This has been the general rule, although some practitioners may allow for faster or slower extrusions depending upon the particular case scenario.

To allow for the teeth to extrude without retaining attachment, we performed a fibrotomy on the tooth for each week of active eruption. This eliminates the need for additional periodontal surgery and allows for a determination of the exact end of active treatment. However, it does expose the patient to a repeated surgical procedure.¹⁵ This technique also allows for the continuous severing of gingival fibers, thus reducing the retention period to approximately four weeks.¹⁶ This technique also has the added advantage of being relatively simple to perform.

There is a difference in the length of retention required to maintain the reorganization of periodontal fibers. In general, the re-arrangement of PDL fibers attached to bone is completed within 28 days.¹⁶ Most reports allow 6 to 12 weeks of retention, although some practitioners like to have retention go on for as long as six months.¹⁶ It is important to stabilize the extruded tooth to prevent it from intruding and returning to its original position. In our cases, the patients were concerned about the length of time the treatment would take because of scheduling conflicts with work. We allowed about six to eight weeks for retention after extrusion.

After the teeth were extruded to the amount necessary for restoring them, we placed temporary acrylic crowns on them. These crowns were checked for proper margins, to allow for healing of the gingival area, and tight contacts (with minor rests), to prevent any relapse of the tooth. The patients were followed up on a weekly basis to ensure that the tooth did not relapse.

The first case described here presented with a situation where the tooth that required eruption was surrounded by fixed bridges and crowns. This situation can be challenging since previously the only other way to use forced eruption was with brackets,^{17,18} bonded bars¹⁹ and removable tissue-born devices.¹²

Since this report was written, two publications have shown devices that look very similar to our described tool. In an article by Filho et al.²⁰ a photo of a device using an acrylic stent appears. The authors do not give any other details about the device, since their paper deals with using implants as anchorage.

Durham et al.¹⁰ use an anchorage device to stabilize the tooth after forced eruption that incorporates a temporary restoration. It is interesting to note that their stabilizing device is very similar to our appliance for forced eruption.

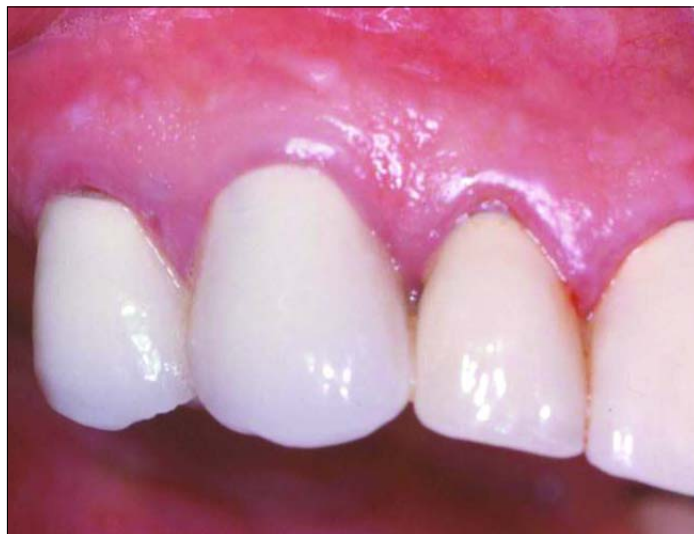

Figure 7. Tooth #6 two and one-half years post-eruption.

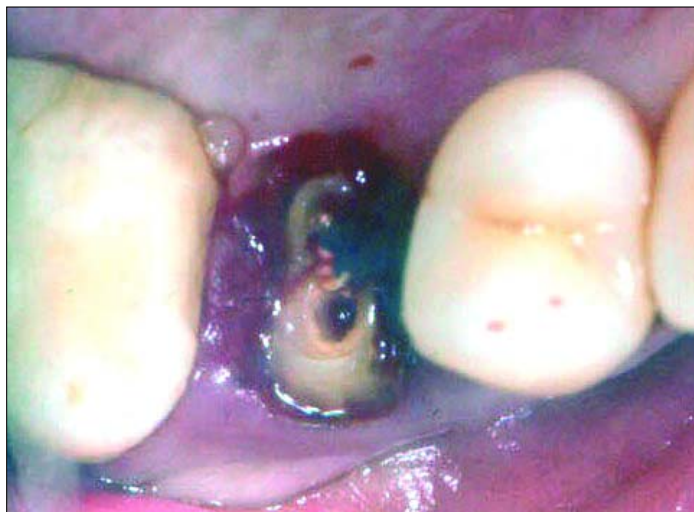

Figure 8. Tooth #13 after caries removal.

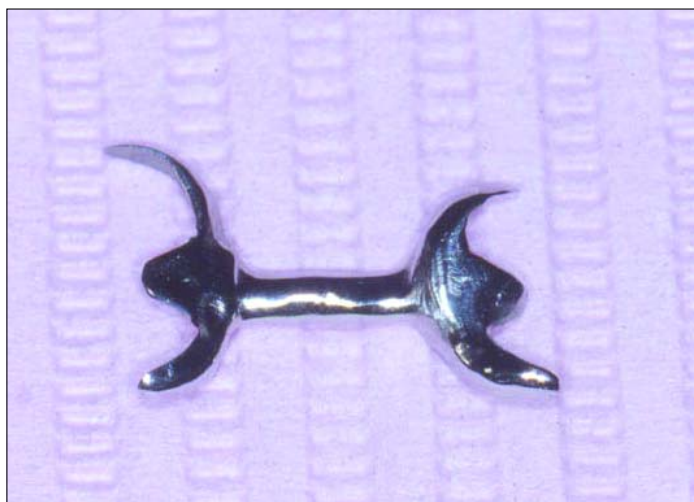

Figure 9. Evolution of Forced Erupter, which is now fabricated to allow easy bonding to adjacent teeth.

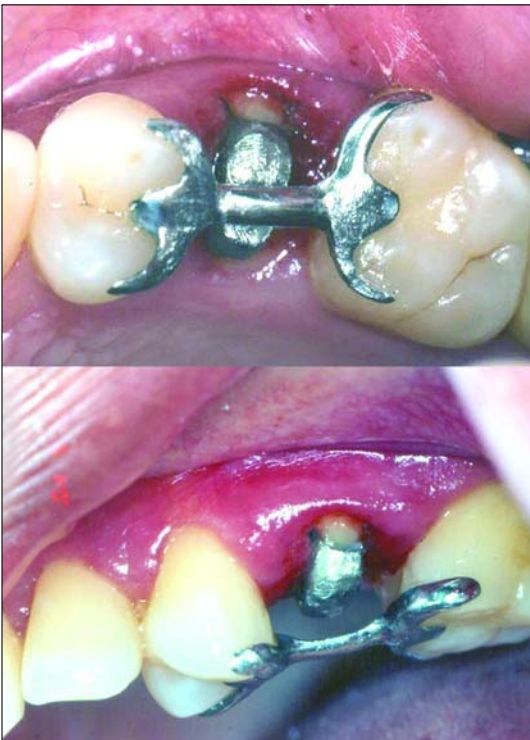

Figure 10. Forced Erupter placed 3 mm below post and then centered with occlusal adjustment.

Here we are presenting an appliance that rests on the adjacent restorations and does not alter them in any way. This Forced Erupter was thought out specifically for these situations and like many new ideas, has gone through changes and experimentation until perfected.

The Forced Erupter itself has evolved since inception mainly because of medical/legal reasons. The first appliance developed was held in place only by the elastomeric tubing. It was possible that during mastication the patient could sever the band and aspirate or ingest the appliance itself. This could have serious consequences, although, thankfully, rarely happens.²¹ This is the reason why the Forced Erupter was changed, as seen in the second case described here, to allow bonding on the lingual to the adjacent teeth. In the second case the Forced Erupter was removed easily with a hemostat when the extrusion was completed.

Conclusion

The device described here for forced eruption can be used easily, efficiently and effectively with nominal expense. The Forced Erupter provides an opportunity to extrude a tooth that might otherwise have been deemed “nonrestorable.” Additionally, it provides minimal consequence to adjacent teeth restorations. Further case reports and studies should be undertaken to evaluate the Forced Erupter supplied with esthetic facings.²² ■

The authors thank Dr. Edwin Rosenberg for his mentorship; Dr. Burton Wasserman for making this report possible; New York Hospital Queens General Practice Residency Program for promoting innovation; Dr. Stephen Kaufman for restoring Case 1; and Dr. Joel Kronberg for restorative assistance in Case 2.

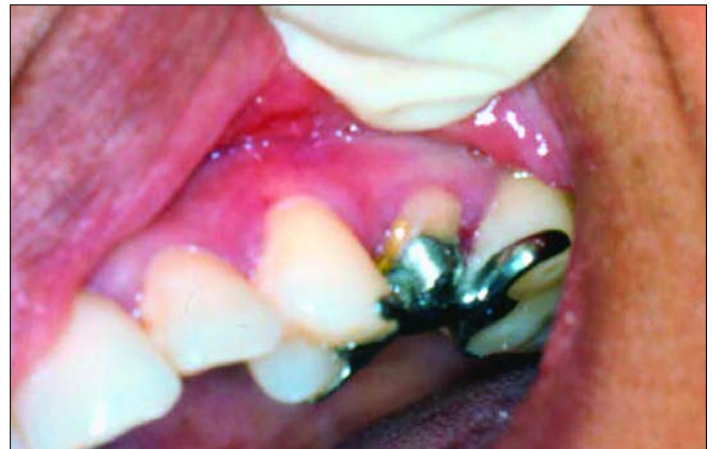

Figure 11. Tooth #13 fully erupted and flush with Forced Erupter's bar.

REFERENCES

- Garrett GB. Forced eruption in the treatment of transverse root fractures. *J Am Dent Assoc* 1985;111:270-2.
- Ingber JS. Forced eruption, Part II: A method of treating nonrestorable teeth—Periodontal and restorative considerations. *J Periodontol* 1976;47(4):203-16.
- Rosenberg ES, Cho SC, Garber DA. Crown lengthening revisited. *Compend Contin Educ Dent* 1999;20(6):527-32, 34, 36-8 passim; quiz 42.
- Mantzikos T, Shamus I. Forced eruption and implant site development: soft tissue response. *Am J Orthod Dentofacial Orthop* 1997;112(6):596-606.
- Levine RA. Forced eruption in the esthetic zone. *Compend Contin Educ Dent* 1997;18(8):795-803; quiz 04.
- Garigulo AW WF, Orban B. Dimension and relations of the dentogingival junction in humans. *J Periodontol* 1961;32:262.
- Stroster TG. Forced eruption: clinical considerations. *Gen Dent* 1990;38(5):376-80.
- Levine RA. Forced eruption, Part II: Esthetic treatment of nonrestorable teeth. *Compendium* 1988;9(2):136-8, 40.
- Heithersay GS. Combined endodontic-orthodontic treatment of transverse root fractures in the region of the alveolar crest. *Oral Surg Oral Med Oral Pathol* 1973;36(3):404-15.
- Durham T, Goddard T, Morrison S. Rapid forced eruption: A case report and review of forced eruption techniques. *General Dentistry* 2004;48:167-175.
- Murchison DF, Schwartz RS. The use of removable appliances for forced eruption of teeth. *Quintessence Int* 1986;17(8):497-501.
- Al-Gheshiyan N. Forced eruption: restoring nonrestorable teeth and preventing extraction site defects. *General Dentistry* 2004;50:327-333.
- Assif D, Pilo R, Marshak B. Restoring teeth following crown-lengthening procedures. *J Prosthet Dent* 1991;65(1):62-4.
- Johnson GK, Sivers JE. Forced eruption in crown-lengthening procedures. *J Prosthet Dent* 1986;56(4):424-7.
- Zyskind K, Zyskind D, Soskolne WA, Harary D. Orthodontic forced eruption: case report of an alternative treatment for subgingivally fractured young permanent incisors. *Quintessence Int* 1992;23(6):393-9.
- Kozlovsky A, Tal H, Lieberman M. Forced eruption combined with gingival fibrotomy. A technique for clinical crown lengthening. *J Clin Periodontol* 1988;15(9):534-8.
- Bielak S, Bimstein E, Eidelman E. Forced eruption: the treatment of choice of subgingivally fractured permanent incisors. *ASDC J Dent Child* 1982;49(3):186-90.
- Ingber JS. Forced eruption: alteration of soft tissue cosmetic deformities. *Int J Periodontics Restorative Dent* 1989;9(6):416-25.
- Ziskind D, Schmidt A, Hirschfeld Z. Forced eruption technique: rationale and clinical report. *J Prosthet Dent* 1998;79(3):246-8.
- Filho L, Soria M, Lima E, Costa C. Orthodontic extrusion anchorage in osseointegrated implants: a case report. *General Dentistry* 2004;52(5):417.
- Tiwana KK, Morton T, Tiwana PS. Aspiration and ingestion in dental practice: a 10-year institutional review. *JADA* 2004;135:1287-1291.
- Hummel SK. Esthetic veneers for use with forced eruption procedures. *J Prosthet Dent* 1993;69(3):346-7.